

**PINNIPED FORENSIC,
NECROPSY AND
TISSUE COLLECTION GUIDE**

Leslie A. Dierauf, V.M.D.

August 1994



**U.S. Department of Commerce
National Oceanic and Atmospheric Administration
National Marine Fisheries Service**

PINNIPED FORENSIC, NECROPSY AND TISSUE COLLECTION GUIDE

Leslie A. Dierauf, V.M.D.

Edited by: Dean Wilkinson and Cindy Driscoll, D.V.M

**NOAA Technical Memorandum
NMFS-OPR-94-3
August 1994**

**U.S. Department of Commerce
Ronald H. Brown, Secretary**

**National Oceanic and Atmospheric Administration
D. James Baker, Under Secretary for Oceans and Atmosphere**

**National Marine Fisheries Service
Rolland A. Schmitten, Assistant Administrator for Fisheries**



The National Marine Fisheries Service (NMFS) does not approve, recommend or endorse any proprietary product mentioned in this publication. No reference shall be made to NMFS or to this publication in any advertising or sales promotion which would indicate or imply that NMFS approves, recommends or endorses any proprietary product mentioned herein, or which has as its purpose an intent to cause, directly or indirectly, the advertised product to be used or purchased because of this NMFS publication.

PINNIPED NECROPSY AND TISSUE COLLECTION GUIDE

TABLE OF CONTENTS

page

1	Introduction
1	Legal Authority For Pinniped Handling and Care
2	Pinniped Identification
2	General Principles
2	Photography
2	Data Characterization
2	Levels
3	Codes
3	Purposes of Tissue Collection
4	Clinical Pathology
4	Blood
4	Blood Collection Equipment
5	Blood Collection Tubes
5	Blood Collection Techniques in Pinnipeds
10	Biopsies
11	Skin and/or Fat
11	Liver
12	Bone Marrow
13	Miscellaneous
13	Life History Information
13	Pertinent Information
13	Pinniped Standard Measurements
18	Standard Necropsy Procedures in Pinnipeds
18	Gross Necropsy
18	Equipment Necessary
20	Standard Necropsy Form
24	In General
24	General External Examination
27	Descriptors For Use During Necropsy Reporting
27	Describing
27	Anatomical Locations
28	Size
28	Color
28	Shape and Form
29	Consistency
29	Odor
29	External Examination of the Carcass

29	First
29	Haircoat
30	Body Orifices
31	Peripheral Lymph Nodes
31	Mammary Glands
31	Scrotum
31	Internal Examination of the Carcass
31	Positioning the Carcass
31	Opening the Abdominal Cavity
35	General Conditions and Observations
35	Stomach
36	Small Intestine
36	Large Intestine
36	Mesenteric Lymph Nodes
37	Pancreas and Pancreatic Ducts
37	Spleen
37	Liver
38	Gall Bladder and Bile Duct
38	Adrenal Glands
38	Kidneys
39	Ureters
39	Bladder and Urethra
39	Reproductive Organs
39	Female
39	Ovaries and Oviducts
40	Uterus and Cervix
40	Vagina and Vestibule
40	Male
40	Testes and Vas Deferens
41	Prostate
41	Penis
41	The Thoracic Cavity
42	Diaphragm
42	Ribs
42	The Neck
42	Thyroids and Parathyroids
42	Esophagus
43	Mediastinal Lymph Nodes
43	Thymus and Brown Fat
43	The Pluck
43	Trachea and Mainstem Bronchi
44	Lungs and Bronchiolar Lymph Nodes
45	Heart
46	The Nervous System

51	COLLECTION, PREPARATION AND PRESERVATION OF TISSUES AND SPECIMENS
51	Histopathology
51	Additional Equipment Recommended
51	Collection and Preparation of Tissues
51	Preservation of Tissues
52	Checklist of Histopathologic Specimens
53	Parasitology
53	Additional Equipment Recommended
53	Collection, Preparation and Preservation of Specimens
54	Bacteriology
54	Additional Equipment Recommended
54	Collection and Preparation of Tissues
55	Preservation
56	Immunology
56	Additional Equipment Recommended
56	Collection, Preparation and Preservation of Tissues
57	Mycology
57	Additional Equipment Recommended
57	Collection and Preparation of Tissues
58	Preservation
58	Virology
58	Additional Equipment Recommended
58	Collection, Preparation and Preservation of Tissues
59	Toxicology
59	Biotoxins
59	Additional Equipment Recommended
59	Collection and Preparation of Tissues
60	Heavy Metal and Anthropogenic Organics
60	Additional Equipment Recommended
61	Collection and Preparation of Tissues
63	Shipping and Laboratory Analytical Techniques
64	Miscellaneous Diagnostic Specimens
65	Isoenzymes
65	Cytochrome P-450
65	DNA Studies
66	Tooth/Bone/Skeletal Preparation
66	Additional Equipment Recommended
66	Collection and Preparation of Skeletal Remains
66	Tooth Preparation for Aging Pinnipeds

67	SHIPPING/TRANSPORT
67	Packing Materials
67	Shipment of Clinical Pathological Specimens
68	Shipment of Histopathological Specimens
68	Shipment of Microbiological Specimens
68	Shipment of Parasitological Specimens
68	Shipment of Toxicological Specimens
69	Conclusions
	Appendices
72	Appendix A: Formulations for Commonly Used Fixatives
73	Appendix B: Laboratories Accredited by the American Association of Veterinary Diagnostic Laboratories
74	Appendix C: Sample Transfer Record
75	Appendix D: Sample Chain of Custody Form
77	References

FIGURES AND TABLES

<u>page</u>	
7	Figure 1: Otariid Blood Collection Site
9	Figure 2: Phocid Blood Collection Site
10	Figure 3: Hindflipper Blood Collection Site
12	Figure 4: Liver Biopsy Site
14	Figure 5: Sexing Pinnipeds
17	Figure 6: Pinniped Standard Measurements
27	Figure 7: Anatomical Descriptors
33	Figure 8: Making the Initial Incisions in a Pinniped Necropsy
34	Figure 9: Measuring the Blubber Layer Thickness
44	Figure 10: Tracheal Bifurcation in Pinnipeds
48	Figure 11: The Skull Locations to Cut for Removal of the Brain
50	Figure 12: Major Anatomical Structures of the Pinniped Brain
69	Figure 13: Piecing the Puzzle Together
5	Chart 1: Blood Collection Tubes
16	Table 1: Pinniped Standard Measurements
19	Chart 2: Sample Label
21-23	Table 2: Standard Necropsy Form
26	Table 3: Decision Matrix for Pinniped Tissue Collection
52	Chart 3: Specimen Checklist for Histopathology

INTRODUCTION

The Oxford Old English Dictionary defines *pinni/ped* as "pinni" -- pertaining to wings or fins or feathers, and "ped" as footed; or -- one who "flies through the water, as if on wings".

The term *forensic* comes from the Latin word *forum* and means -- pertaining to, connected with, or used in courts of law; or -- suitable or analogous to pleadings in court.

Guide is defined as "one who shows the way, especially to a beginner, novice or traveler in a strange country", or something that guides.

This *Pinniped Forensic Guide* is a book of instruction and information for beginners, novices or travelers in a new land, a guide when working with those marine mammals classified as pinnipeds. The following instruction on collection, preparation, preservation and shipment of pinniped tissues and other specimens, will help provide the most trustworthy data for potential use as evidence in a court of law.

This manual's intent is to assist stranding network volunteers (with little or no formal scientific training), basic scientists (with a general knowledge of mammalian physiology) and professional marine mammal experts in performing simple and sophisticated specimen collection procedures. Whether your responsibility for pinnipeds is on the beach, in the postmortem room, or in an academic or commercial laboratory facility, the procedures and methodologies discussed in this manual should assist you in your efforts. The final goal is to generate supportive scientific data for diagnosing the cause or causes of stranding and unusual mortality events involving pinnipeds.

LEGAL AUTHORITY FOR PINNIPED HANDLING AND CARE

In the United States, legal authority for working with pinnipeds is shared among the Departments of Commerce, Interior and Agriculture. The U.S. Department of Agriculture's Animal and Plant Health Inspection Service (APHIS) concentrates on animal welfare and humane care and transport of pinnipeds under the Animal Welfare Act (AWA; 7 USC 2131-2155). The U.S. Department of the Interior's Fish and Wildlife Service (FWS) implements management actions with regard to walrus. The U.S. Department of Commerce's National Marine Fisheries Service (NMFS) is charged with primary responsibilities for all other pinniped species under the Marine Mammal Protection Act of 1972 (MMPA; 16 USC 1361-1421h).

In order for any person to "take" a pinniped from U.S. waters or shores, that person, institution or commercial business must apply for and be issued a permit or letter of authorization (LOA) from the NMFS's Office of Protected Resources. Each

permit or LOA allows the taking of a pinniped for a specific purpose, such as rescue and rehabilitation, the protection of the public, scientific research or public display. The actual definition of "take" as stated in the MMPA is "to hunt, capture, kill, harass, or attempt to hunt, capture, kill or harass". Without a permit or LOA, the MMPA specifically states that capturing or harassing pinnipeds or collecting pinniped body parts is prohibited.

PINNIPED IDENTIFICATION^{1,2}

All walrus, sea lions, fur seals and seals fall into the Order Carnivora, Suborder Pinnipedia. Pinnipeds are amphibious, air breathing mammals that divide their time between waters and lands of the marine environment. Their bodies are streamlined, and their appendages are shortened and flattened. Pinniped hindlimbs are paddle-like with webbed distal appendages. There are three families of pinnipeds, the odobenids (walrus), the otariids (the "eared" sea lions and fur seals) and the phocids (the "earless" or true seals).

GENERAL PRINCIPLES

PHOTOGRAPHY:

In the necropsy room, a good quality camera with a 50 mm lens and an additional macro lens for close-up shots is essential. Use the camera to document genus and species (if unsure), to catalog unusual lesions or organs discovered during the course of the examination, and to augment any descriptions made about particular conditions, that may be of scientific or legal interest. Include any photographic documentation in the pinniped's permanent hospital/necropsy file.

A video camera can also be used to document specific observations during a necropsy procedure, but a video record cannot entirely substitute for clear, detailed photographic documentation.

DATA CHARACTERIZATION (Levels and Codes)^{3,4}:

Data collection on pinnipeds can be prioritized into 3 categories:

Level A, basic minimum data, including names and addresses of principle in stranding event, date, exact location of event, sex(es), length and condition of the animal(s);

Level B, supplementary on-site data, including basic life history and specific event data, such as weather, carcass orientation, animal and human activities in the area, collection of parts for age determination, etc.; and,

Level C, necropsy examination and parasite collection, including results of careful external and internal examination of the animal, tissues and/or specimens collected, preserved and shipped/transported to other facilities.

In addition, tissue/specimen quality is categorized by Code:

Code 1, the live animal;

Code 2, the freshly dead ("carcass in good condition") animal;

Code 3, the decomposed ("carcass in fair condition") animal;

Code 4, the severely decomposed ("carcass in poor condition") animal; and,

Code 5, the mummified or purely skeletal remains animal.

PURPOSES OF TISSUE COLLECTION:

For the science of pinniped medicine and pathology to advance, the importance of complete record-keeping and standardized operating procedures cannot be overemphasized. The quality of data collected and collated is directly dependent upon the quality control procedures and methodologies, whether on the beach, in the necropsy room, in the clinical laboratory or in the computer laboratory.

It is the live animal that is the most valuable for collection of materials that might yield a rapid diagnosis regarding ongoing disease processes. Unfortunately in the case of marine mammals, the live animal is found least often; therefore, it is imperative, if given the opportunity, that the most skilled and best trained personnel collect data from the live pinniped, ideally a veterinarian.

It is crucial then, that live (Code 1), rescued pinnipeds undergo complete physical examinations, blood collections for complete blood counts and total chemistry profiles, and fecal examinations for the presence of parasites or parasitic ova. If time and the animals' conditions allow, further diagnostics--including, but not limited to, additional blood chemistry and serology studies, radiography, ultrasonography, electrocardiography, urinalysis, nasal/tooth/throat/anorectal microbiological swab cultures and sensitivities, endocrine function tests and tissue biopsies--should be performed to allow for the most complete data collection and the most accurate causative diagnoses. Live pinnipeds, rescued and rehabilitated, should be appropriately tagged, released, and monitored following release.

CLINICAL PATHOLOGY

BLOOD

BLOOD COLLECTION EQUIPMENT:

Collection of blood for clinical pathological examination in pinnipeds normally requires appropriate restraint of the animal. Handling of a pinniped, particularly an adult pinniped, can be difficult, and it is best to have all necessary equipment pre-assembled and close at hand prior to restraining the animal. The equipment should include:

1. mechanical restraint equipment^{5,6};
2. chemical restraint equipment⁷;
3. emergency medical supplies ("crash cart");
4. needles, of varying lengths and gauges;
5. syringes, of varying sizes;
6. betadine or nolvasan solution in spray bottle or as swabs;
7. blood collection tubes of all types (see below);
8. microscope slides and coverslips;
9. Diff-Quik^a or new methylene blue stain;
10. microscope
11. indelible marker pen or pencil for labels;
12. laboratory forms for submission of samples; and
13. hospital record to note any observations, emergency situations or other observations during blood collection.

^a Diff-Quik, Harleco, Gibbstown, NJ

BLOOD COLLECTION TUBES⁸:

Following is a listing of commonly used blood collection tubes:

<u>Color-Coded Top</u>	<u>Chemical in Tube</u>	<u>Use This Tube For</u>
RTT, red top tube	none	serum chemistries serum iron sterile collection vial
LTT, lavender top tube	EDTA	complete blood count blood typing
GrTT, green top tube	heparin	serum chemistries, ammonia, parasites, amino acids, chromo- somes, sulfanilates
GTT, gray top tube	sodium fluoride, potassium oxalate	glucose, activated clotting time
BTT, blue top tube	sodium citrate	clotting factors (including PT, PTT)
BITT, black top tube	soybean thrombin, snake venom	fibrin degradation products
BWTT, black & white	Michel's media	viral pathology

BLOOD COLLECTION TECHNIQUES^{3,4}:

When collecting blood from pinnipeds by any of the techniques discussed below, follow these general rules. Use sterile, standard gauge needles, syringes, and collection tubes. During aspiration, try not to put the blood coming into the collection system under pressure (do not pull back hard or fast on the syringe barrel; use a butterfly catheter collection system if collapsing vessels are a problem).

After collection, if serum is desired, let the sample in the red top tube sit in an upright position for 15 to 20 minutes so that the clot retracts. Never leave the serum sitting above the clot longer than an hour. Once the clot is retracted, centrifuge the specimen (making sure to balance the blood tube with a "blank" tube filled with an equal amount of water) for 5-10 minutes. Remove the specimen tube, and, using a clean pipette or syringe, gently aspirate the serum sitting on top of the red blood cells. Place the serum in a new red top tube, and label it for transport to the laboratory.

Send the sample to the laboratory immediately; if this cannot be done, keep the specimen refrigerated (at 4° C). Serum not sent to a laboratory can be stored frozen (at -20° C) for possible future use.

Blood deteriorates rapidly following death. Results from blood collection in dead animals (those characterized as anything other than Code 1) are questionable at best. If blood collection is performed at all on a dead animal, it must be done immediately after death to be of any value at all. Serum from a recently dead animal (no more than 4 or 5 hours)⁹ can be used for bacterial or viral serological testing; the best collection site is often the atrium of the heart or the posterior vena cava. Post-mortem serum should not be used for electrolyte or enzyme values, since these values are immediately changed at the time of death, and can be misleading. If a serum sample is desired from a live pinniped, collect blood, as described above, let the specimen sit at room temperature for 10-15 minutes, then centrifuge in a standard blood chemistry centrifuge for an additional 5-10 minutes. Then with sterile needle and syringe aspirate the serum off the top and place it into a sterile red top tube.

Body fluids, cerebrospinal fluid, and joint fluid can also be collected up to 4 to 5 hours post-mortem; place these types of specimens in sterile red top or purple top tubes.

Needle lengths vary, depending on the size pinniped from which blood is being collected. In a juvenile pinniped, use a 1 inch, 18 gauge needle. In an adult pinniped, use a 3.5 inch, 18 gauge needle.

There are 3 typical blood sampling sites for *otariids* and *odobenids* :

-- 1. the caudal gluteal vein --

The caudal gluteal vein allows collection of the largest volume of blood with the least danger to the technician. Locate this vein by restraining the otariid or odobenid symmetrically in ventral recumbency (the animal is on its belly with its foreflippers tucked under it, and its hindflippers straight out behind). Palpate three landmarks: (1) the tail base (where the tail joins the body), (2) the femoral trochanters (top outside portion of the most dorsal hindflipper bone), and (3) the dorsal midline (a line drawn centrally along the spine). Draw three imaginary lines: (1) perpendicular to the tail at the tailbase, (2) perpendicular to the dorsal spine between the femoral trochanters, and (3) 1/3 of the distance from the femoral trochanters to the tailbase and perpendicular to the dorsal midline. Insert the needle (with appropriate size syringe attached) 1/2 inch to 1 inch to the right or left of dorsal midline along line (3) above [Figure 1]¹. Position the needle perpendicular to the skin's surface. Pop the needle through the skin, penetrating to the hub of the

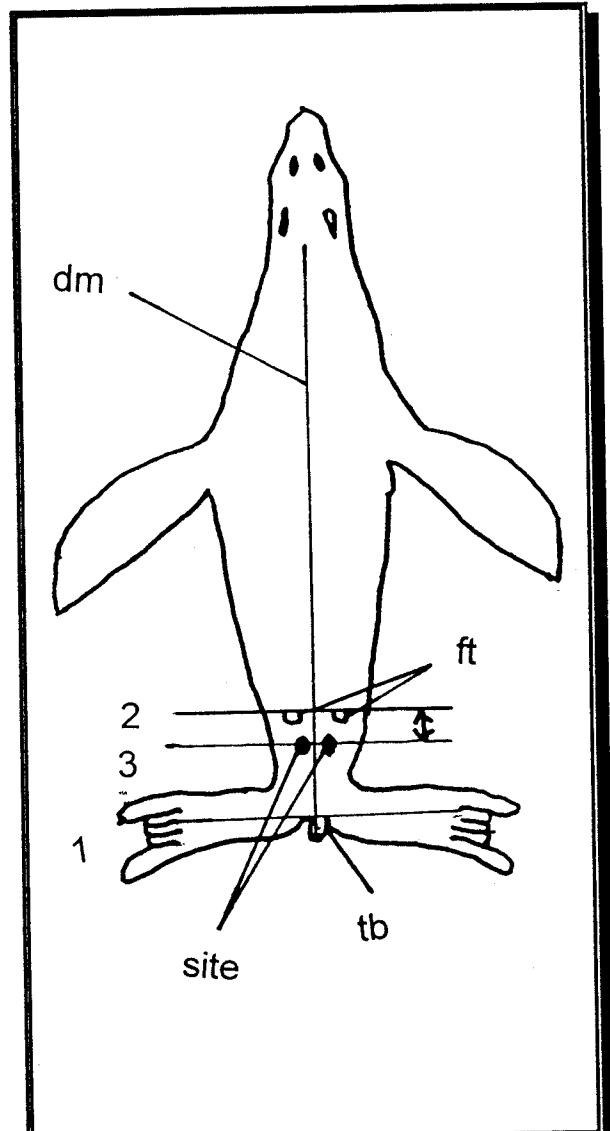


Figure 1 : Location of the Caudal Gluteal Vein in Otariids

=====

KEY:

tb = tailbase

ft = femoral trochanters

dm = dorsal midline

● = blood collection site

needle. Then slowly pull up, aspirating as you do so, until the caudal gluteal vein is entered. The vein is not large, but can be located in this fashion if estimates are accurate and needle lengths are appropriate.

-- 2. the interdigital veins of the hindflipper --

The interdigital veins in the webbing of each hindflipper are not particularly large and can often be constricted in cool temperatures. To dilate the veins, either place the animal in a heated room with careful supervision, or, use a heating apparatus, such as an athletic heat pack, or hot compresses on the webbed surface of the hindflipper. Use the interdigital veins only if the animal appears healthy. Once the blood sample is obtained, apply firm pressure for at least a minute or two to the affected interdigital area to prevent hematoma formation.

-- 3. the precaval vein --

This venipuncture site is used when blood is essential and no other site is available for use. The precaval vein is located at the heart base on the right side of the otariid. Palpate the sternum (the breast plate), the trachea and the ribs on the left and right sides of the body. At the level of ribs 3 to 5, just to the right of the animal's sternum, insert the needle perpendicularly (attached to the appropriate size syringe) and aspirate to obtain the blood sample.

There are 2 common blood collection sites in *phocids* :

-- 1. the extradural intravertebral vein --

The extradural intravertebral vein is relatively easy to find and produces an adequate blood sample volume in phocids. Restrain the seal symmetrically in ventral recumbency (the animal lying on its belly with its hindflippers straight out behind). Palpate for the dorsal spines of the thoracic and lumbar vertebrae, until lumbar vertebrae 3 and 4 are located. Insert an 18 gauge needle with attached syringe between the two vertebral bodies, perpendicularly and slowly, but continuously, to the needle's hub. If the needle hits bone, walk the needle cranially or caudally off the bone until the intravertebral space is entered. Once in the extradural venous sinus, aspirate the blood sample desired [Figure 2].

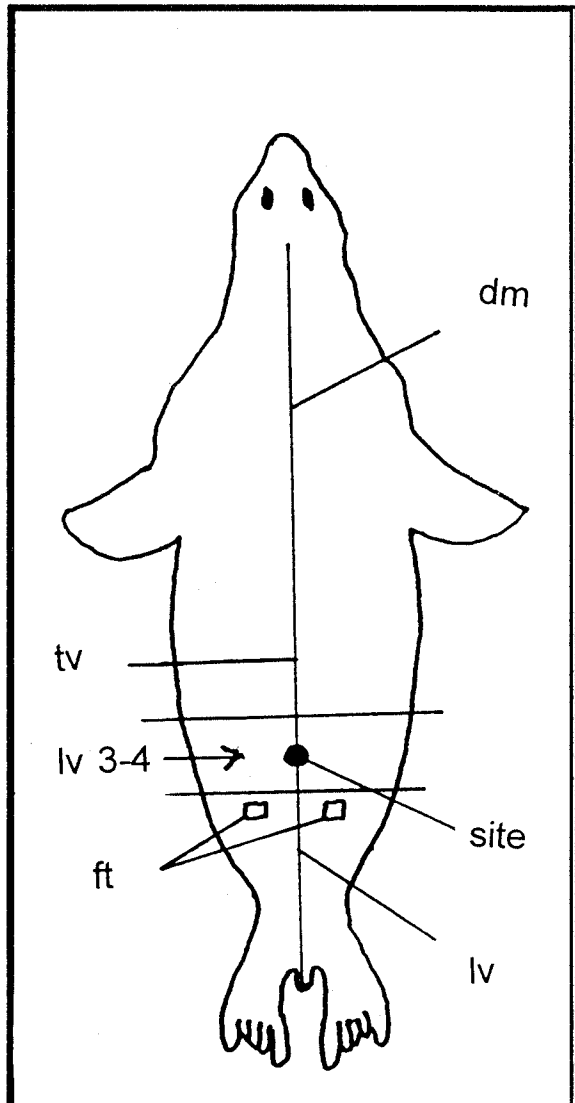


Figure 2 : The Extradural
Intravertebral Vein in Phocids

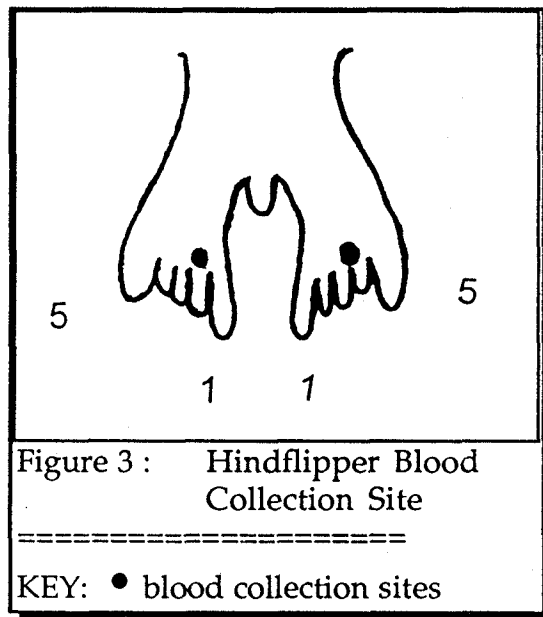
=====

KEY:

- dm = dorsal midline
- ft = femoral trochanters
- tv = thoracic vertebrae
- lv = lumbar vertebrae
- = blood collection site

-- 2. the ventral (plantar) interdigital veins of the hindflipper --

The ventral interdigital veins are located similarly to those in the otariid; however, the diameter of these phocid veins is smaller. Over the second digit, or just to the medial side of the fourth digit (as the hindflipper sits, straight out behind the animal, digit one is the most medial of the digits on the hind-flipper, digit five is the most lateral [Figure 3]), at the trailing edge of the interdigital webbing, insert the needle (with syringe), almost parallel to the skin at about a 10 to 20° angle. The blood collected here will be an arterial-venous mixture, so be certain to apply pressure to the area after blood collection is complete to avoid a hematoma from forming.



BIOPSIES¹⁰

Any live pinniped undergoing a biopsy must be properly restrained with appropriate infiltration of local anesthetic agent at the biopsy site. **Only Trained Veterinarians Should Perform Invasive Procedures.** In pinnipeds, before attempting any biopsy, it may be necessary to remove the hair overlying the area of concern. In any case, the area of concern should be surgically prepped using a betadine or nolvasan scrub and 70% alcohol, prior to initiating any biopsy procedure. Proper handling of tissues for biopsy includes avoiding crushing, rough handling or cauterizing. If shrinkage is expected (especially with skin or muscle), it is best to remove the biopsy specimen and gently lay it in its normal configuration on a hard piece of material, such as a piece of cardboard or a popsicle stick, before immersing in fixative. Once full fixation has occurred (3 to 4 days) the tissue may be gently teased off the hard material and left by itself in the formalin.

SKIN and/or FAT BIOPSY:

A skin biopsy is the simplest biopsy to perform, should such a sample be needed for diagnostics. Skin biopsies generally are used to diagnose dermatologic disease or are used for genetic life history determinations. Whenever collecting a skin specimen, be certain to include both normal and abnormal tissue in your sample. Two methods are routinely used:

(1) Using forceps and scalpel, excise (cut out) about a 1 cm² piece of skin tissue. Fat or blubber may also be removed at this time. Close the incision using one or two interrupted, absorbable sutures. If fat or blubber is being collected for toxicologic or contaminant analysis, for standardization, the sample should be collected from under the skin overlying and just cranial to the sternum's xiphoid process along the ventral midline of the pinniped. In the live animal, sample size will necessarily be smaller than that in the dead animal.

(2) Using a commercially available biopsy punch^b, made in various bore diameters (4 mm is a commonly used size), place the punch in contact with the skin and use slight pressure and a rotating motion to obtain a core of skin and blubber. Once obtained, the core is grasped with forceps and elevated, and any connective tissue severed to remove the "plug" of tissue. The skin is closed with one or two interrupted sutures.

If the biopsy is being taken for histopathology, the punch or needle sample should be teased into a container of 10% formalin for fixation (For further detail on fixation and fixation solutions see Appendix A, page 72).

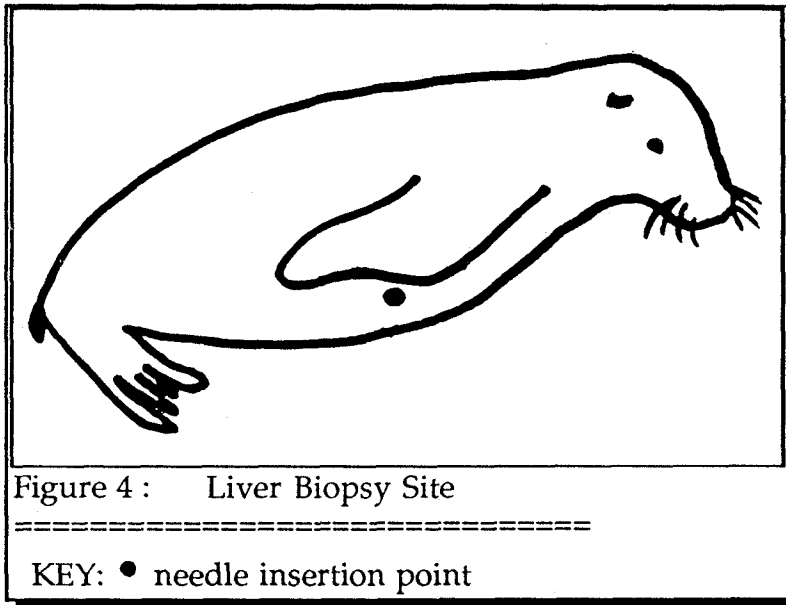
LIVER BIOPSY:

The veterinarian may choose to perform a liver biopsy if any of the following indications exist during initial physical examination and diagnostic work-up: jaundice/icterus, elevated liver enzyme levels, elevated bilirubin levels, or a history of exposure to toxicologic, biologic or other hepatotoxic agents. Biopsy of the pinniped liver is performed with the live animal under general anesthesia and using a commercially available biopsy needle. The preferred needle is a 5.25 inch, 16-gauge Manghini liver biopsy needle^c. To collect an adequate liver biopsy, the pinniped must be chemically restrained in left lateral recumbency (with the right side up) [Figure 4].

^b Biopsy punch made by Baker/Cummins, Miami, FL

^c Manghini liver biopsy needle, Kormed, Minneapolis, MN

Liver biopsy in the California sea lion is performed on the right side of the body wall. To locate the exact site, place the right foreflipper back and flat against the right body wall. Where the foreflipper flexes at its carpus [Figure 4] is the insertion point. Be certain to position the right foreflipper mid-way between the dorsal spine and ventral body wall to avoid penetrating the pleural space (lung field). Insert the needle via a short, quick, penetrating action. Try not to penetrate the pleural space (lungfield). The biopsy core is aseptically transferred to a container of 10% formalin for fixation prior to histopathologic examination.



BONE MARROW:

Bone marrow biopsies can be used routinely and provide excellent diagnostic information regarding pinniped immunologic status, hematologic capacities and potential neoplastic (cancerous) activities. In pinnipeds, palpate the femoral trochanter. Over this area, make a 2 cm surgical incision. A Jamshidi^d bone marrow needle is used to penetrate the center of the trochanter area to a level of about 3 cm. Remove the bone marrow biopsy needle stylet and aspirate bone marrow material with a sterile 12 cc syringe.

Place a small portion of bone marrow tissue on a clean microscopic slide. Smear it out (as with a blood smear), and allow to air dry. Take the remaining biopsy material and place in a vial of 10% formalin.

^d Jamshidi bone marrow biopsy needle, Kormed, Minneapolis, MN

MISCELLANEOUS BIOPSIES:

Fine-needle aspiration biopsies¹¹ can be used to collect cytological materials from external lesions, or from any suspected internal areas. Aspiration biopsies are easy, quick, and capable of yielding excellent diagnostic information on the spot, assuming microscopic equipment is available.

Use a sterile set-up of a 22- or 25-gauge needle attached to a 12 ml syringe. Insert the needle into the area or lesion you wish to investigate. Aspirate, rapidly pulling the plunger at least half way up the barrel, creating negative pressure. Without removing the needle, reposition it in another location within the area of consideration, and repeat. Gently withdraw the needle (still attached to the syringe) from the lesion. Gently pull back on the plunger, bringing 1 to 2 ml of air into the syringe. Expulse the material in the needle hub onto at least three clean glass microscope slides. Make a smear of the aspirate on each slide, as you would for blood count differentials. On one of the slides, place one or two drops of new methylene blue stain and a coverslip, or, as with a blood smear, stain the slide with Diff-Quik. Send the other two air-dried needle aspirate smears to the laboratory for further analysis. It is best to call the laboratory prior to obtaining the specimen to ask the preferred method of aspirate collection and preparation.

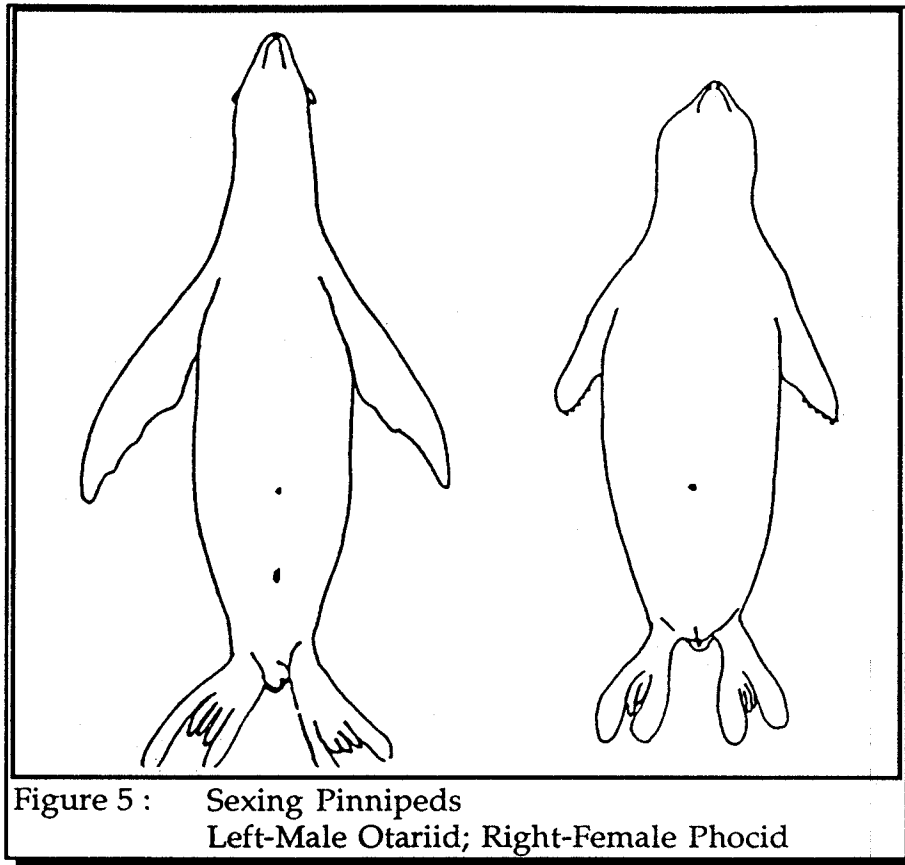
LIFE HISTORY INFORMATION

PERTINENT INFORMATION:

Pinniped life history information, including age, sex and reproductive history deduced from ovarian structures, can be critical for assessing population trends, forensic data and contaminant analysis data.

Determine the genus and species of the pinniped (See references under Pinniped Identification).

Determine the sex of the pinniped. Differentiating male from female pinniped is most easily accomplished by rolling the animal over on its back and examining for a penile orifice just caudal to the umbilical scar. Adult male otariids may be identified by noting the scrotal sac posteriorly, but if the sac is drawn close to the body, this may be difficult; remember, that in phocids there is no scrotal sac. In young animals, it may be difficult to actually see the penile orifice through the lanugo coat; however, there is often urine staining, and the os penis (penile bone) can always be palpated through the skin [Figure 5].



Weigh the pinniped, and record the weight on both the standard measurement and necropsy forms. As you perform a necropsy, specific organs should be weighed as well (See Standard Necropsy Form and Specimen Checklist for Histopathology on pages 21-23 & 52).

Determine the age of the pinniped, if possible. Age determination without history is difficult and speculative. The best indicator of age is the tooth. Remove a canine or postcanine tooth, and process it appropriately (see Section on Tooth/Bone/Skeletal Preparation).

Other specimens to collect that will assist the pinniped life historian in data collection are¹²:

- (1) Whole skull (for morphometrics);
- (2) Lower jaw (with teeth present);
- (3) Stomach and stomach contents (for feeding habits, nutritional information and biotoxinant presence);

- (4) Reproductive organs (ovaries can indicate pregnancies, testes can indicate maturity);
- (5) Fetus (for developmental characteristics and deformities);
- (6) Milk (for nutritional status of mother and for handraising formulation);
- (7) Parasites (for developing baseline and evolutionary information, including nutritional status and feeding and haul-out habits); and
- (8) Prey items (intact species from the pinniped's habitat for comparison purposes, and for feeding habit information).

[See Table 3 and Section on Specimen Collection]

PINNIPED STANDARD MEASUREMENTS:

To the clinician, technician or volunteer, the importance of taking standard external measurements on pinnipeds is not altogether clear. But without this information, life history scientists, policy makers, and conservation specialists, who must research and protect populations of animals in the wild, have greater difficulty in devising management decisions. It is extremely important to these decision-makers to know whether the animal being examined is normal size for its age, in good flesh, and of correct morphometric dimensions for its particular genus and species.

Standard measurements in pinnipeds should be performed on live animals at the time of initial examination if possible. In the live animal, it may not be feasible to collect more than the standard length, curvilinear length, axillary girth, umbilical girth, flipper lengths and widths and tail length. Record all data in metric measurements. The numbers or letters next to the specific measurements refer to the numbers and letters in Figure 6. Always be certain to weigh the animal, sex the animal, and make an estimate of the animal's age.

In a dead animal, be certain to record all life history information, as well as take a right upper canine tooth for exact aging of the animal. The importance of life history information cannot be overemphasized, as it characterizes whole populations of marine mammals, and allows the scientists to begin to develop a scenario as far as population dynamics are concerned.

Record the number and type (incisors, canines, post-canines) of teeth in upper and lower arcades (jawbones) to aid in further pinniped life history identification¹³.

TABLE 1: PINNIPED STANDARD MEASUREMENTS

(record in kg and cm)	(record in cm)
0. Body Weight _____	11. Widest Hindflipper Length _____
1. Standard Length _____	12. Tail Length _____
2. Curvilinear Length _____	<u>Skull Measurements</u>
3. Axillary Length _____	A. Rostral Width _____
4. Umbilical Girth _____	B. Interorbital Width _____
5. Eye Length _____	C. Zygomatic Width _____
6. Ear Length _____	D. Cranial Width _____
7. Anterior Length of the Foreflipper _____	E. Condylbasal Length _____
8. Axillary Flipper Length _____	F. Rostral Length _____
9. Widest Foreflipper Length _____	G. Length of Upper Postcanines _____
10. Anterior Length of the Hindflipper _____	<u>Internal Measurement</u>
	13. Blubber Thickness _____

The following shows required standard body measurements for pinnipeds [Figure 6].

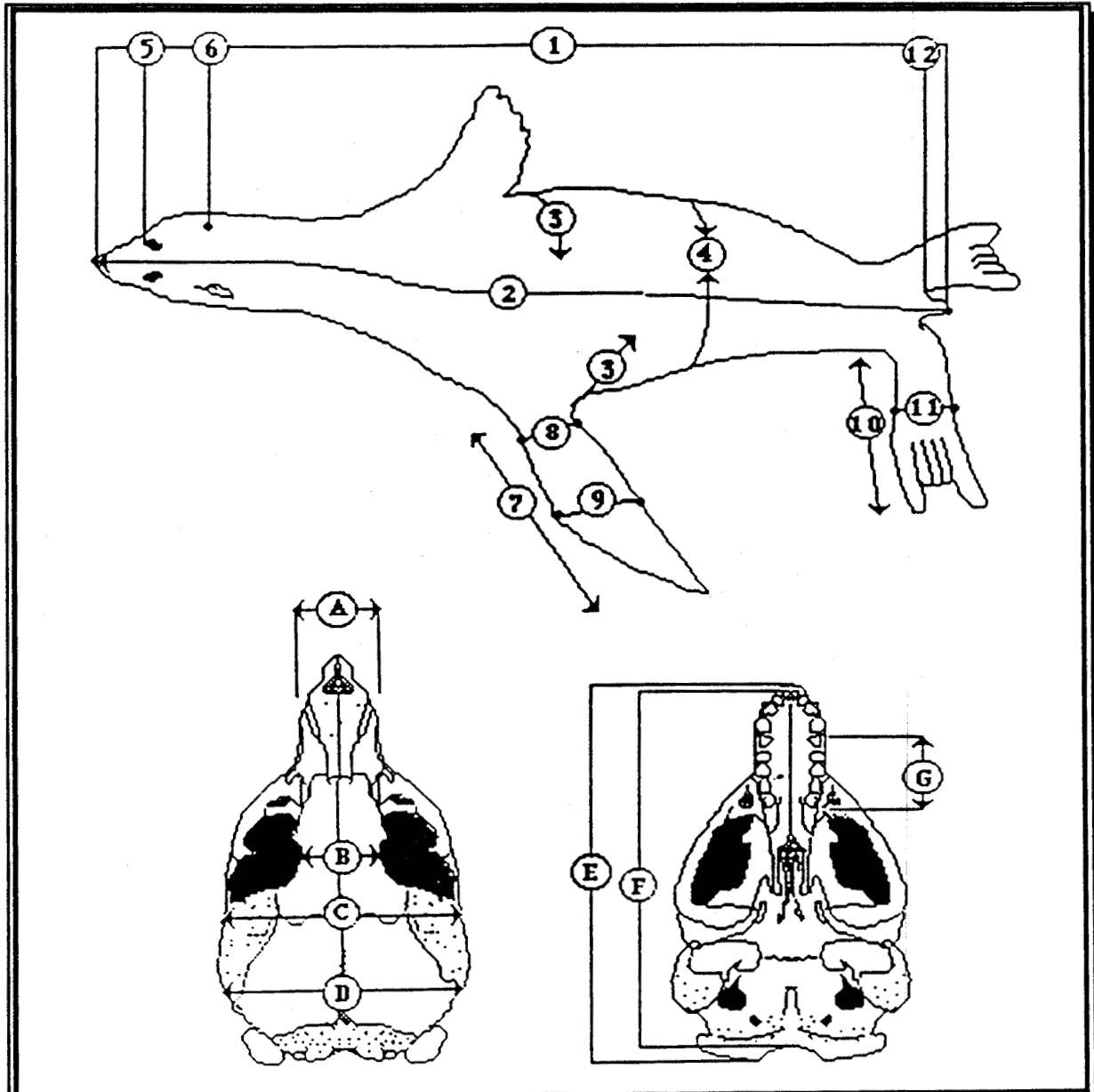


Figure 6 : Pinniped Standard Measurements

Number and Letter Labels Refer to
Table of Pinniped Standard Measurements

STANDARD NECROPSY PROCEDURES IN PINNIPEDS

GROSS NECROPSY

EQUIPMENT NECESSARY:

Camera, 35mm, with 50mm and macro (close-up) lenses, flash and extra batteries; Video camera, if available (the video camera should not substitute for clear and accurate photography)
 Protective clothing (plastic gloves (preferably talc-free), boots, aprons)
 Surgical mask and protective eyeglasses (to guard against public health risk)
 Record sheets (including standard necropsy form and standard measurement sheet), soft lead (no. 2) pencils and clipboard
 Walk-on scale and wheelbarrow for weighing whole animal
 Flexible and metal tape measures (minimum 5 yards, with centimeter markings)
 Plastic/wooden ruler, graded in centimeters and inches
 Tooth dental elevator
 Dissecting tray or board
 Sharp high quality stainless steel knives (curved and/or straight, minimum 6 inch blade)
 Sharpening steel
 Scalpel blades (assortment of #10s and #15s) and handle
 Small and large dissection scissors
 Long and short-handled, tissue and rat-toothed forceps
 Pruning shears, bolt cutters, or oscillating (Stryker) or electric saw (for cutting bone and cartilage)
 Bone rongeurs (for removing small bony fragments)
 Heavy duty rubber gloves (able to be disinfected and cleaned)
 Cotton string (for tying off fluid filled hollow organs, i.e stomach, etc.)
 Spring or platform weighing scale (20 kg capacity)
 Postal scale or other weighing device (in mg & gram weights)
 Paper towels
 Tyvek Labels and indelible ink pens/ permanent markers (non-smearing) [see example of label front & back below]
 Containers for collected samples (see Section on Shipping)
 Fixatives (10% Formalin; also see Appendix A)
 Alcohol (70% ethanol)
 Various sterile blood collection tubes, syringes and needles
 Whirl-Pak^e or zip-lok plastic bags
 Aluminum foil (heavy duty)
 Covered barrel for solid waste disposal

^e Whirl-Pak, Fisher Scientific, Englewood, CO

Specimen Label	
Date:	-----
From:	----- -----
Animal ID Number:	-----
Genus & Species:	----- -----
Sex:	-----
	Age: ----- (over)

(front)

To:	----- ----- -----
Comments	----- ----- -----
Contact for Add'l Info	
(tel):	-----
(fax):	-----
Information (bac Label k)	

STANDARD NECROPSY FORM:

A great deal of important comparative data can be lost if the clinician or technician concludes that there is "not enough time" to write up a report, or "the findings are not significant enough to record". If there is enough time to perform a necropsy, writing the report is part and parcel of that necropsy. The importance of records, particularly in a court of law, cannot be overstated.

The following standardized necropsy form is recommended for a methodical, step-by-step assessment of organs and lesions post-mortem. Tissue samples should be routinely collected from all organs, whether they appear grossly normal or abnormal. When sampling abnormal tissue, be certain to collect adjacent normal tissue. This standardized necropsy form allows a worthwhile, item by item examination that is relatively rapid and error-free; it also provides consistency, whether the reporter is clinician, technician, or volunteer.

The person performing the necropsy must always legibly sign the necropsy form, so that examination information can be traced back, if necessary, at a later date. Some facilities require that necropsy reports dictated and/or transcribed during actual necropsy procedures be formally typed up for distribution and/or reporting purposes. The original handwritten and signed document prepared at the time of necropsy should routinely be kept on file for future reference, be it of a legal or scientific nature.

**TABLE 2: STANDARDIZED NECROPSY FORM FOR PINNIPEDS
ADMINISTRATIVE INFORMATION**

- | | |
|--------------------------------------|--|
| I. Administrative Information | 1. Date |
| 2. Facility Name | |
| 3. Pinniped Genus | 4. Species |
| 6. Animal Identification Number | 5. Sex |
| 8. Necropsy Personnel | 7. Other Id (tags etc.) |
| 10. Time of Death (24 hr) | 9. Attending DVM |
| 12. Time of Necropsy(24 hr) | 11. Died/Euthanized/Other (explain) |
| 14. Photographs Taken | 13. Location of Necropsy (city,county,state) |
| 16. Weight of Animal (kg/lb) | 15. Name of Photographer |
| | 17. Age of Animal/Tooth Taken (circle one) |

Ancillary Administrative Information

Stranding Information:

- | | |
|---|-------------------------------|
| 18. Date of Stranding | 19. Time of Stranding (24 hr) |
| 20. Exact Location of Stranding | |
| 21. All same species of Pinniped? | 22. Number of Animals |
| 23. If not all same, numbers by Genus and Species | |

Weather Information:

- | | | |
|--|---|----------|
| 24. Weather Conditions (circle as many as necessary) | clear, partly cloudy, overcast, rainstorm, snowstorm, windstorm,
thunder, lightning, sand storm, fog, other conditions (explain) | |
| 25. Wind Direction | 26. Wind Speed | |
| 27. Tides | 28. Swells/Waves | 29. Moon |
| 30. Water Temperature | 31. Air Temperature | |

Other Historical Information:

32. Fish run/Plankton bloom ongoing? (explain)
33. Any geographical abnormalities near stranding site? (explain)
34. Any geological abnormalities near stranding site? (explain)
35. Any industrial/urban/agricultural entities near site? (explain)
36. Any other causes of concern near the site? (explain)
37. Any medical problems obvious in animals? (explain)
38. Any clinical signs present in animals? (explain)
39. Any other historical information not already included above?

(explain)

**STANDARD PINNIPED NECROPSY FORM
GROSS NECROPSY INFORMATION**

II. Gross Necropsy Information

General Condition (circle applicable descriptions)

40. Carcass condition Code (2, 3, 4, 5)
 41. Postmortem condition (good, fair, poor, mummified)
 42. Nutritional state (overweight, fat, thin, emaciated)
 43. State of hydration (good, slightly dehydrated, moderately dehydrated, severely dehydrated, unknown)
 44. Haircoat (normal, hair loss, oil, molting, scruffy, parasites,
 45. Skin (normal, cracking, bleeding, dried, moist, smooth, rough, wounds, infection, masses, parasites, scars)
 46. Nails (normal, present, absent, torn, bleeding, cracked, crushed)
 47. Peripheral lymph nodes (palpable, obvious, unnoticeable, other)

Star (with an asterisk *) each tissue taken for analysis

Body Orifices (describe what you see)

48. Mouth and teeth
 49. Nose
 50. Eye, left
 51. Eye, right
 52. Ear, left
 53. Ear, right
 54. If male, Penile orifice
 55. If female, Vulva
 56. Anus

Abdominal Cavity (describe what you see)

57. Relative position of organs
 58. First impressions on opening the abdominal cavity

Describe Conditions of Organs and Tissues, Any Lesions

59. Peritoneum
 60. Stomach
 61. Duodenum
 62. Small intestine
 63. Large intestine
 64. Mesenteric lymph nodes
 65. Pancreas
 66. Spleen
 67. Liver
 68. Gall bladder and bile duct
 69. Adrenal gland, left
 70. Adrenal gland, right
 71. Kidney, left
 72. Kidney, right
 73. Ureter, left
 74. Ureter, right
 75. Bladder and urethra

Reproductive Organs**FEMALE--**

- 76. Ovary and oviduct, left
- 77. Ovary and oviduct, right
- 78. Uterus and cervix, left
- 79. Uterus and cervix, right
- 80. Vagina and vestibule
- 81. Mammary glands

MALE--

- 82. Testicle and vas, left
- 83. Testicle and vas, right
- 84. Prostate
- 85. Penis and os penis
- 86. Prepuce

Thoracic Cavity (describe what you see)

- 87. Diaphragm
- 88. Relative position of organs on opening the thorax
- 89. First impressions on opening the thorax

Describe Conditions of Organs and Tissues, Any Lesions

- 90. Lung, left
- 91. Lung, right
- 92. Ribs, left side
- 93. Ribs, right side
- 94. Mediastinal lymph nodes
- 95. Pleura
- 96. Thymus
- 97. Brown fat

The Neck (describe what you see)

- 98. Thyroid and Parathyroid, left
- 99. Thyroid and Parathyroid, right
- 100. Esophagus

The Pluck (describe what you see)

- 101. Tongue
- 102. Laryngeal Area
- 103. Trachea
- 104. Mainstem bronchus, left
- 105. Mainstem bronchus, right
- 106. Bronchioles

The Heart (describe what you see)

- 107. Pericardium
- 108. Myocardium
- 109. Endocardium
- The Valves:
- 110. Tricuspid
- 111. Pulmonic
- 112. Mitral
- 113. Aortic
- The Chambers:
- 118. Right atrium
- 120. Right ventricle
- The Vessels:
- 114. Pulmonary vein
- 115. Pulmonary artery, right
- 116. Pulmonary, left
- 117. Dorsal aorta
- 119. Left atrium
- 121. Left ventricle

The Nervous System (describe what you see)

- 122. Brain
- 123. Spinal cord
- 124. Peripheral nerves

OTHER COMMENTS OR REMARKS: (include extra page if necessary)

IN GENERAL:

Be certain when performing any necropsy or tissue collection procedures on pinnipeds to wear protective gear, including surgical gloves, mask, and apron, if possible. Thoroughly disinfect instruments before and after the procedure. Protective gear and disinfection are recommended to minimize the potential risk of necropsy personnel acquiring any microbiological or chemical contaminant from the pinniped being examined.¹⁴

Gross pathological protocol is an important first step for the diagnostician in determining potential causes of death and disease. Necropsy (from the Greek "to view death") or post-mortem examination involves a complete external and internal examination of the dead animal.

Gross necropsy, as with other forms of medicine and forensics, is as much an art as a science. Before any description can be written, a thorough and consistent examination of all organs and lesions (called a necropsy, or animal autopsy) must be performed. An assistant can be most helpful; the assistant can write and weigh organs, as you perform and describe the lesions and organs you see. Whether you have an assistant or not, it is most important to write the report as you perform the necropsy or directly afterward, so as not to forget or omit any information from the description. Descriptions that are the most useful are simple, clear, and without interpretation. Describe only what you see. Perform the necropsy in a methodical manner, one system at a time, in the same order each time. Always describe each organ or lesion's size, color, shape, consistency, location, texture on cut surface, odor (if any), general description and weight. Record size and weight metrically, to coincide with observations others might make on similar animals. If you see no obvious abnormalities grossly, record "no significant lesions" (NSL) or "no significant observations" (NSO). As the examiner performs more and more necropsies, the powers of observation will improve and become accurate, precise and succinct. Practice makes perfect.

GENERAL EXTERNAL EXAMINATION:

Examine the skin, appendages (flippers, tail, head) and body orifices for wounds, oil/tar, hair loss, external parasites, texture changes (cracking, bleeding, drying, moisture, smoothness) and condition of the nails (present, absent, torn, bleeding). Unless the species of pinniped you identify is listed as threatened or endangered, remove a canine tooth for aging purposes. If the exact age of the pinniped is known, you need not remove a tooth. If the pinniped is a listed species, do not remove a tooth until you contact your regional NMFS office for further instructions.

In general, for ease, efficiency, and conciseness, the person performing the necropsy examination should examine the following decision matrix to determine tissues and collection media that might be necessary to help the clinician and/or diagnostician determine the cause or causes of death in the pinniped under consideration [Table 3].

At the time of gross necropsy, at the time each lesion, organ or tissue is examined--

1. Collect sample for histopathology, including normal and abnormal appearing tissue in the sample (see pages 51-52);
2. Collect representative parasites seen grossly (see pages 53-54);
3. Collect, aseptically (without contamination), sample for microbiology, including bacteriology, virology and mycology (see pages 54-59);
4. Collect appropriate tissues or specimens for toxicological analysis, using clean cutting instruments, with all instruments being wiped clean between sampling^f (see pages 59-63);
5. Collect any other tissues or specimens that might be necessary for the clinician/diagnostician to make a diagnosis (see pages 64-65).

Each of these 5 procedural areas will be discussed independently and in detail beginning on page 51 below, but remember to consider them as a continuum if the cause of death is unknown. Collecting duplicate samples, sending one set of tissues for analysis, and archiving the second set on-site, insures the availability of samples at a later date if additional analysis or rechecking of results is necessary. These rules are especially important if there is any concern that the data from tissues or specimens collected may be necessary for use in a court of law.

^f For optimum results use high carbon stainless steel instruments cleaned with deionized water

ANALYSIS FOR:		MICROBIOLOGY					TOXICOLOGY					MISCELLANEOUS				
		Parasites	Bacteria	Immunology	Fungi	Viruses	Biotoxins	Heavy Metals	Organochlorines	Aromatic Hydrocarbons	Carbamates	Tumor	Nutritional	Isoenzymes	Cytochrome P-450	DNA Studies
USE THE FOLLOWING PREPARATION:																
Fixatives	10% Formalin	X			X	X	X				X					X
	70% Ethanol	X														
	2.5% Potassium Dichromate	X														
	AFA Solution	X														
	Physiologic Saline	X										X				
	3% Glutaraldehyde					X										
	Trisodium Phosphate															X
Containers	Covered Plastic Jar					X				X	X					
	Sterile Swab/Culturette		X		X	X										
	Sterile Red Top Tube	X	X		X	X					X		X			
	Sterile Purple Top (EDTA)			X											X	
	Dermatophyte Test Media				X											
	Michel's Media					X										
	Screwtop Polyethylene Vial							X						X		
	Acid-rinsed Glass Jar							X	X							
	Whirl-pak/Zip-loc Bags		X		X	X		X		X						
	Aluminum Foil								X	X						
	Blue Top Tube (citrate)											X				
Other	Whole Blood	X		X			X	X	X	X		X				
	Serum			X		X	X	X	X	X					X	
	Plasma														X	
	Biopsy				X											
	Tissue		X			X	X				X		X	X		
Temperature	Room									X						
	Refrigerated (4 C)	X	X	X			X					X			X	
	Frozen (-20 C)			X		X	X	X	X	X		X	X			
	Dry Ice					X	X	X	X	X		X	X			

Table 3: Decision Matrix for Pinniped Tissue and Specimen Collection

DESCRIPTORS FOR USE DURING NECROPSY REPORTING ¹⁵

DESCRIBING ANATOMICAL LOCATIONS:

Initially describe each organ or lesion by its location within the body cavity, as well as its relationship to other organs or structures. Become familiar with anatomical descriptors for organ and organism position [Figure 7]:

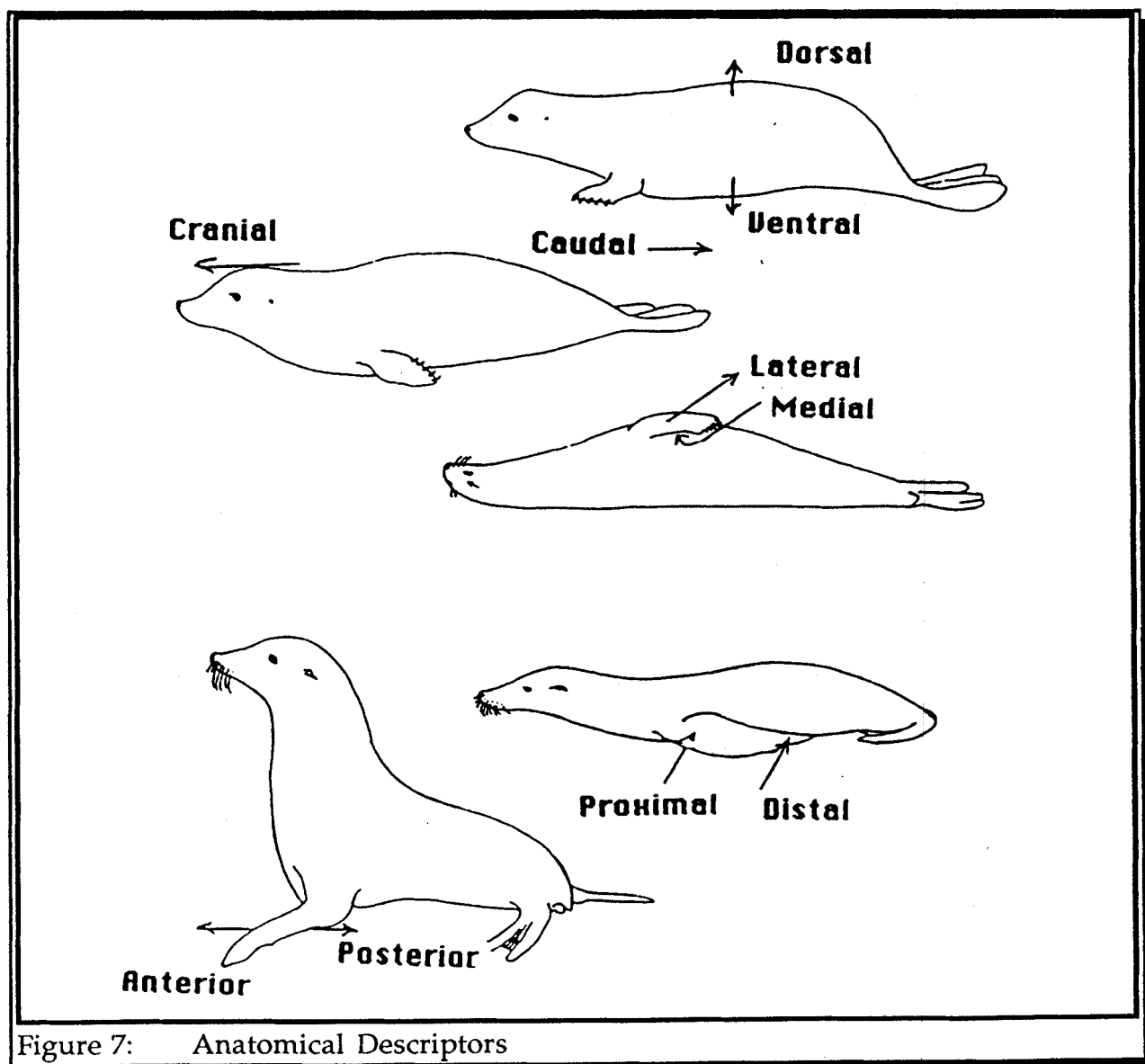


Figure 7: Anatomical Descriptors

Dorsal	- of, toward, on, in or near the back
Ventral	- pertaining to the lower side or undersurface
Cranial	- toward the head
Caudal	- toward the tail
Lateral	- of, relating to, or situated on the side(s)
Medial	- relating to, lying or extending toward the middle
Proximal	- nearer to the main body of the organ or organism
Distal	- away from the main body of the organ or organism
Anterior	- on the forward leading edge
Posterior	- on the backward trailing edge

DESCRIBING SIZE:

Always accurately describe size. Do not say "small", or "larger than normal", record metric length, width or diameter, and metric wet weight (this is the weight when the organ is freshly removed). A millimeter/centimeter ruler should be on hand for accurate measurement. If a metric ruler is not available, score your forefinger from joint to joint, so that you can estimate centimeters.

DESCRIBING COLOR:

The easiest way to describe color if it is not a standard primary color, is to use a descriptor that refers to a common everyday item (food is a good choice). In addition, other adjectives and adverbs, such as mottled, shiny, pale, streaked, blotchy, and dark are words used to describe organ or lesion color.

DESCRIBING SHAPE AND FORM:

Describe what you see, using descriptors. The following words¹³ are merely suggestions: oval, ovoid, spherical, round, egg-shaped, discoid, square, cuboidal, rectangular, triangular, wedge-shaped, spindle-shaped, long, slender, flattened, domed, swollen, bulbous, indented, lobulated, lace-like, spongy, narrowed, patent, dilated, open, tortuous or branching. Cut-surfaces can be described as swollen, bulging, shiny, dull, eroded, glistening, scaly, pitted or oozing. The terms amorphous, shapeless or irregular can be used if there are no definite shapes or patterns, or the shape is too erratic to describe. If you have performed a number of necropsies and recognize that the shape of a particular organ is normal, you may record a phrase such as "of the usual shape".

DESCRIBING CONSISTENCY:

This is an easy category. Descriptions here may be plain and simple, such as firm, hard, soft, flabby, fluid-filled, sharp-edged, or friable (falls apart with any amount of pressure). If any fluids are present, they should also be described, such as cloudy, turbid, clear, thick, bloody, dark or pus-like.

DESCRIBING ODOR:

Do not overlook your sense of smell; it can be an excellent indicator of pathological processes. With a fresh specimen, there is rarely any obvious odor. Sweet, sour, rancid, ammonia-like, fetid, putrid, fermentative, petroleum-like, or similar descriptors are useful.

EXTERNAL EXAMINATION OF THE CARCASS**First**

Weigh the animal and take standard pinniped measurements.

Note the presence of any tag/identifying marks on the pinniped.

Collect appropriate samples [See Table 3 and Section on Collection, Preparation and Preservation of Tissues and Specimens] . Mark Samples taken on checklist for Histopathology.

Note the condition of the carcass (Code 2, 3 or 4). Note the animal's general body condition; is the animal in good flesh, thin, or emaciated (ribs showing)? Is the animal dehydrated? The skin turgor/fallback test can be used to check hydration, but if the condition of the carcass is not absolutely fresh, or there is a large amount of blubber present, this test may be unreliable. If performed, a flap of skin between the animal's shoulder blades is lifted and left to fall back down; rapid fall indicates good hydration; if the flap hesitates before falling back flush with the body, the animal can be considered dehydrated.

Hair Coat

All pinnipeds, except walruses, have hair overlying their skin. Odobenids (walrus) are hairless with raised, irregular "blebs of scar tissue-like" skin. Most otariids and phocids have dense hair coats of varying lengths and densities, depending on the particular species. Phocids and otariids, adults and neonates, go through hair coat molts, with the phocids more likely sloughing hair in sheets, while otariids can shed and regrow a portion of their hair coats almost unperceptively each year; note any hair coat changes.

Do not be confused by droplets of water on pinniped pelage; these areas can appear dark and shiny, but should not be confused with actual skin or hair coat lesions.

Body Orifices

All seven body orifices (mouth, nose, eyes, ears, penile orifice, vulva, anus) should be examined for wounds, parasites, pus, blood or other abnormalities.

In the oral cavity, examine the tongue, the teeth (which can be stained a blotchy black or brown in pinnipeds), and note any abnormalities. If the animal is very freshly dead, note the color of the mucous membranes (pink, white, blue, red).

The nose in elephant seals often has a normal white, pasty, nasal discharge. Other phocids, otariids, or odobenids do not normally have a nasal discharge. Look closely for parasites, discharges, wounds, foreign bodies, or other lesions in the nasal passages.

Pinniped eyes are not easily opened. The pinniped eye has a third eyelid located medially and ventrally. In each eye, note any discharge, wounds, abrasions, foreign bodies, or other lesions.

The ear in phocids and odobenids is no more than an external hole on each side of the head. In otariids, each ear has an external flap, called a pinna, which differs in length and shape depending on the species. For each ear, note any discharge, wounds, abrasions, foreign bodies, or other lesions.

In the male pinniped, posterior to the umbilicus, is the penile orifice, where urine and sperm exit the body. The penis is hidden under subcutaneous fat, rather than hanging ventrally as in terrestrial mammals. Note any discharge or swelling at the orifice. Extend the penis by grasping the os penis. Note any lesions.

In the female, just ventral to the anus, is the vulva. Note its color, shape, and any swelling, discharge, wounds or other lesions that might be present.

The anus is located under the tail of the pinniped; it is the most dorsal orifice located on the animal's posterior. Note the presence of any discharge, diarrhea, wounds, or other lesions.

Peripheral Lymph Nodes

Peripheral lymph nodes are not easily located in pinnipeds due to either subcutaneous fat or to thick pelage (hair coat). If obvious on external examination, be sure to note lymph node location and any abnormalities.

Mammary Glands

Female pinniped mammary glands lie in the subcutaneous fat under the skin and tend to follow the general contour of the abdominal body wall. They are not normally visible unless there is milk, infection or other abnormalities present. Normally, the nipples are retracted under the hair coat and are often described as "inverted". Otariids (seal lions, fur seals) and odobenids (walrus) have four mammary nipples (teats), two anterior to the umbilicus and two posterior to the umbilicus, one on each side of the ventral midline. Phocids (true seals) have two abdominal mammary teats, either two directly adjacent to or two directly posterior to the umbilicus.

Scrotum

Testicles sit in a scrotal sac only in the otariids, and because the sac is closely adhered to the body wall, is not easily visible. Phocid testicles are not present in a scrotal sac but lie deep in the subcutaneous fat of each inguinal area.

INTERNAL EXAMINATION OF THE CARCASS

Collect appropriate samples [See Table 3 and Section on Collection, Preparation and Preservation of Tissues and Specimens] .. Mark Samples taken on checklist for Histopathology as appropriate.

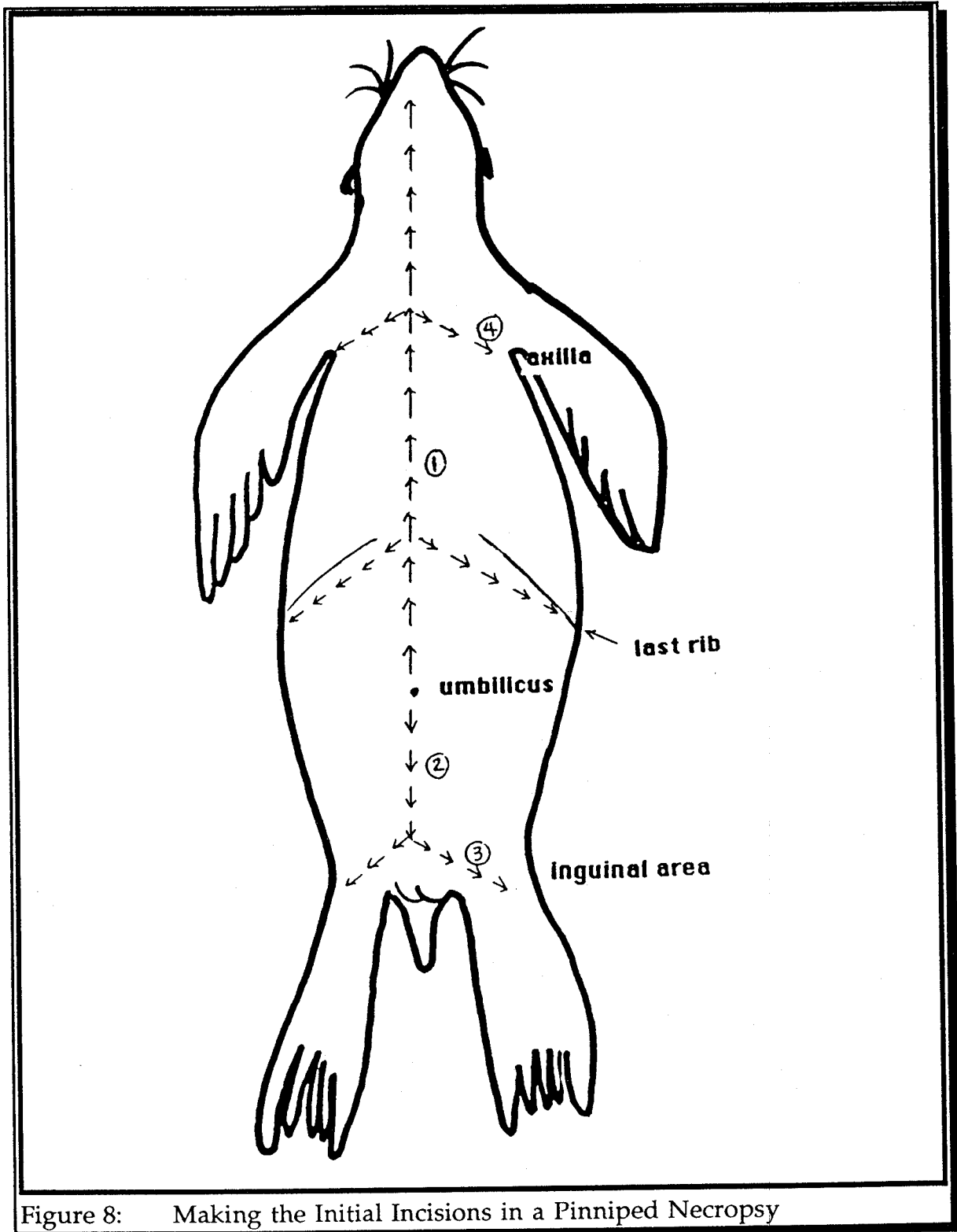
Positioning the Carcass

The pinniped is positioned in dorsal recumbency (the animal is on its back and symmetrically positioned with its four appendages out to the sides) [Figure 8].

OPENING THE ABDOMINAL CAVITY

Using a knife (if the pinniped is large) or a #10 scalpel blade (if the pinniped is small) incise (cut) the skin on the ventral midline just cranial to the umbilicus. Continue to incise cranially along the ventral midline to just under the level of the chin [Figure 8 @ 1]. As you make the incision, extend it into the blubber layer of the animal if it exists. -- NOTE: Thin or emaciated pinnipeds may not have a thick blubber layer; also fur seals will not normally have a blubber layer. In these cases,

take care not to incise the chest or abdominal cavities as you make your skin incision. -- Extend the skin incision similarly, but caudally from the umbilicus [Figure 8 @ 2]. -- NOTE: If the animal is a male, avoid the os penis and penile orifice by taking the incision to the left around these organs. -- Continue the incision caudally to the left inguinal (groin) area [Figure 8 @ 3].



Notice where the thorax stops and the abdomen begins in a pinniped. Palpate the level at which the ribs stop, approximately two-thirds of the way between the head and tail. Just caudal to the last rib is the start of the abdominal cavity.

Next, make skin flaps on either side of the ventral midline incision, by incising perpendicularly to the midline, both from the chin area to the axillae (armpits) on either side, extending these cuts toward the dorsum [Figure 8 @ 4], and also from the inguinal areas on either side toward the dorsum. Record the color of the blubber and measure the thickness of the blubber layer (the blubber layer is the fatty, adipose tissue layer usually attached directly to the skin as you pull back the flaps). Using a metric tape measure, determine and record the depth of the blubber at its thickest point along the ventral midline incision. You may need to gently dissect downward through the blubber, avoiding penetration into the abdomen or thorax, by using blunt-tipped scissors [Figure 9].

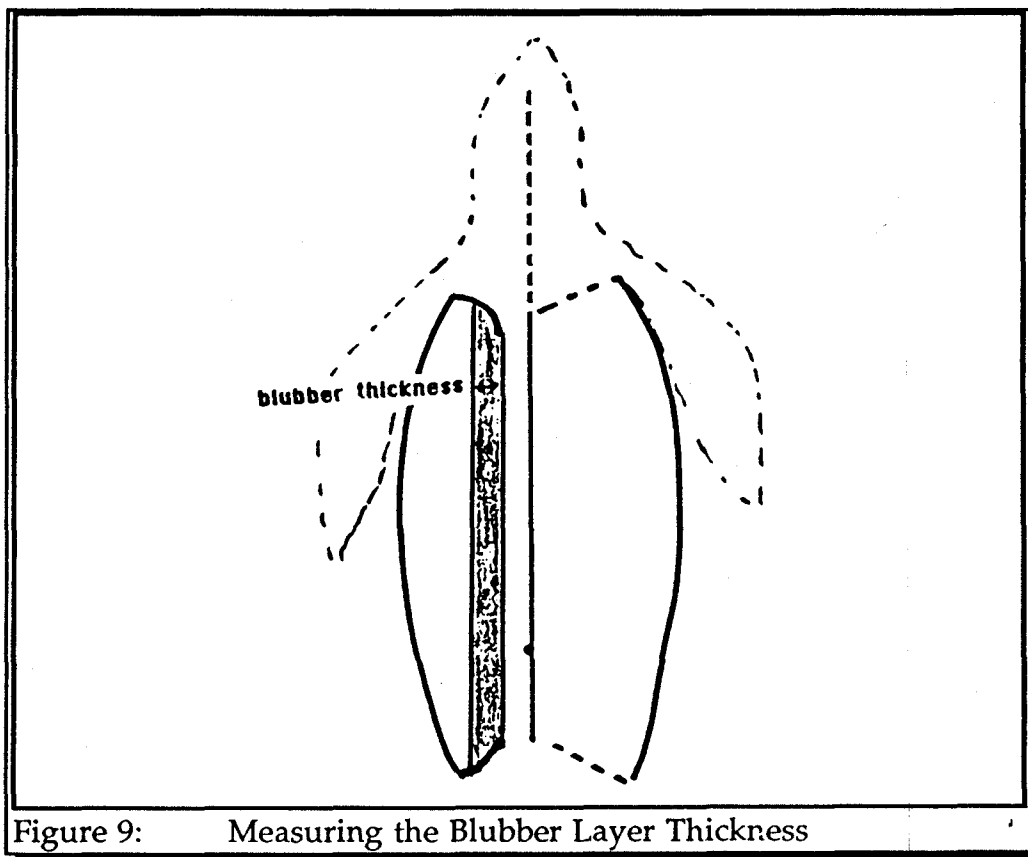


Figure 9: Measuring the Blubber Layer Thickness

Once the blubber measurement is taken, record it on your Pinniped Standard Measurement form (page 16), then pull back the skin/blubber flaps to expose the thoracic and abdominal walls.

Underneath the blubber is a tough, sinewy tissue. The tissue caudal to the ribcage is the muscle overlying the abdominal peritoneum. The peritoneum lines the abdominal cavity, and is in two layers, the outer (ventral) peritoneum (usually covered by a thick layer of muscle) and the inner (dorsal) peritoneum (often only noticed firmly adhered to the ventral peritoneum on reflecting back the peritoneal layer with rat-tipped forceps).

Make a small, sharp stab incision with the scalpel blade through the muscle and peritoneum into the abdominal cavity. Place two fingers inside the hole, spreading the edges laterally (out to each side) and tenting the tissue up. Using blunt-tipped scissors, incise caudally, cutting through both muscle and peritoneum.

Within the abdominal cavity, note the relative position of all organs. Record size, color, shape, consistency of each organ one by one as you systematically examine the abdominal contents.

GENERAL CONDITIONS AND OBSERVATIONS ON OPENING THE ABDOMEN:

The abdominal cavity of a pinniped, is a small compartment, relative to terrestrial mammals, occupying only about the caudal 1/3 of the animal's body length. Overlying the majority of organs in the cranial abdomen is a strong, lacy, somewhat transparent tissue called the omentum. The inner (dorsal) peritoneum (abdominal lining) is very strong and very vascular, with, especially in the larger pinnipeds, a veritable net of blood vessels (called the rete mirabilae, translated as marvelous net) coursing along the inside lining of the dorsal peritoneum.

Peruse the relative position of each organ you can see, noting any abnormal relationships, such as displacement, twisted or entrapped intestinal loops or organ size. Note presence, quantity and/or quality of any fluid within the abdominal cavity.

Also note the general condition of the internal organs and tissues. In general, this observation of general condition should correspond with the external condition of the carcass (Code 2, 3, 4 or 5), which you recorded at the start of the necropsy procedure. Note the relative degree of tissue decay or decomposition (autolysis). If you observe other conditions, such as generalized hemorrhage (bleeding into organ walls or other tissues), generalized icterus (yellow jaundice) or generalized paleness or pallor to the tissues, note them at this time.

STOMACH:

In pinnipeds, unlike cetaceans, the stomach is a single-chambered organ. On incising the stomach wall, there are large, often reddish, rugal folds. Here and in all subsequent section of the gastrointestinal tract, be certain to note any obvious

ulcerated or bruised areas, any hemorrhage, any possible foreign bodies, or any parasites that might be present (some internal parasites may be minute, so look carefully; a hand lens or magnifying glass can be helpful).

If information on food consumption patterns is required, collect fish otoliths (ear bones, specific for each fish species) for identification by life historians. If whole intact prey (food) items are present in the stomach, collect these in sterile zip-loc bags and freeze for identification and/or contaminant or biotoxin analysis (see pages 59-63).

In a normal pinniped, you will note that the stomach lacks an obvious pyloric region (in terrestrial animals the pylorus is a glandular area found at the point where food materials exit the stomach and flow into the small intestine).

SMALL INTESTINE:

The duodenum makes up the initial portion of the small intestine. The duodenum surrounds the pancreas (see below) as it courses caudally toward the jejunum and ileum (the successive portions of the small intestine). The pinniped small intestine in its entirety is not only much longer but more coiled than that seen in terrestrial mammals. In an adult California sea lion, small intestinal lengths up to 33 meters have been recorded.

LARGE INTESTINE:

In pinnipeds there is no true cecum, as is seen in most terrestrial mammals; instead, in pinnipeds, there is simply a small diverticulum (or sac-like pouch) which denotes the start of the large intestine. The large intestine (or colon) is exceptionally short in pinnipeds, usually less than 35 cm in length depending upon the age and species of the pinniped.

MESENTERIC LYMPH NODES:

The mesenteric lymph nodes are located centrally within the mesentery (the stained-glass appearing connective tissue that holds all the intestinal loops in alignment). Unlike terrestrial mammals, these lymph nodes are very large (8 to 9 cm in length) and oblong in shape; they are also very "meaty-appearing" and usually bunched up together in the central portion of the mesentery, rather than spread throughout. A thick capsule surrounds each lymph node; check to see how closely adhered the capsule is to the lymph node by slitting the capsule and attempting to peel it back. Slice through a representative sample of lymph nodes, noting any hemorrhage, bruising, exudate or bulging on cut surface.

PANCREAS AND PANCREATIC DUCTS:

Gently pick up the duodenum (the beginning of the small intestine) in your fingers, and follow it along noting the pink meaty tissue lying adjacent to the duodenum. This is the pancreas; in the pinniped, it is a very large organ located "in the embrace of the duodenum". Visually examine and manually palpate the pancreas, noting any apparent nodules, masses, hemorrhages or exudates.

Note the main pancreatic duct (the tube running centrally through the soft tissue mass of the pancreas) and the several lesser ducts (branching off from the main). Once visually examined, make a 6 cm long cut in the lateral duodenal wall. Gently milk the main duct of the pancreas with your right hand as you use your left hand to somewhat elevate the duodenum up for viewing. Pancreatic juices (generally white) should flow out the pancreatic duct and exit into the duodenum. Note duct patency (do the pancreatic secretions flow easily?) and the consistency of the fluid as it enters the duodenum. Then, using scissors, cut the main pancreatic duct open longitudinally, following its flow toward the duodenum, checking as you do so for any areas of hemorrhage, bruising, secretions, excretions, parasites or other abnormalities.

SPLEEN:

The pinniped's spleen is located, as in other mammals, on the right side of the abdomen (the left side as you look into the abdomen from the ventral midline). The spleen in pinnipeds, relative to domestic animals, is only of moderate size, and often has small, dark, homogeneously pigmented areas throughout, which contain hemosiderin (a non-pathologic iron pigment). Note any discolorations, raised areas, or apparent nodules or masses. Also note the thick, capsule covering the spleen; slit the capsule and attempt to peel it back.

LIVER:

The liver of the pinniped takes up a considerable portion of the cranial abdomen, lying against the muscular diaphragm and adjacent and dorsal to the stomach (deep in the abdominal cavity under the stomach at necropsy). The pinniped liver is very large, multi-lobed, and has a considerable number of natural fissures (or slits) in it. To thoroughly examine the liver, make representative cross-cutting slices ("bread-loafing") through all lobes, noting the organ's consistency as you do so. Also note any areas of discoloration, nodular occurrences, exudates or parasites within the parenchyma (deep tissue) of the organ.

GALL BLADDER AND BILE DUCT:

The gall bladder is a green-tinted organ, usually located centrally or just off-center, within the mass of the liver. Be certain to note the size and relative fullness of this fluid-filled organ.

To check bile duct patency, use the 6 cm long incision made in the wall of the duodenum during examination of the pancreatic duct. Gently squeeze the gall bladder; bile (green fluid) should flow down the bile duct (tube) and exit into the duodenum in the same area as the pancreatic duct entered. Note bile duct patency (does the bile flow easily?) and fluid consistency as it enters the duodenum.

ADRENAL GLANDS:

In the pinniped the adrenal glands are very large and oblong. They are located adjacent to the cranial end (pole) of each kidney, but are much more obvious than in most terrestrial mammals because of their size. The adrenal glands are very meaty and, on cut surface, they bulge and exhibit soft, sometimes vacuolated centers. In addition, on normal adrenal gland cut surface, there is a lighter-colored cortical area surrounding an inner darker-colored medullary area. The right adrenal gland is generally larger than the left.

KIDNEYS:

Pinniped kidneys look similar to cow kidneys, in that they are very lobular (multiple 2 to 3 cm clumps of kidney all connected together). Both kidneys are located deep against the dorsal surface of the abdominal cavity, with the right kidney located slightly more caudally, relative to the left kidney.

Each kidney is encased in an extensive venous net (called a superficial venous plexus); these venous nets tend to be more obvious surrounding phocid (the true seals) kidneys rather than otariid (sea lions and fur seals) kidneys. Because each lobule is composed of up to 100 individual kidney units (nephrons/reniculi), on kidney cut surface each unit of the kidney exhibits a complete cortex (the light colored tissue, located peripherally in each unit) and medulla (the dark colored tissue located centrally in each unit). Slice each kidney longitudinally (from pole to pole), noting its consistency (excess fibrous tissue? mushy texture?), any areas of discoloration, bruising, hemorrhage, exudate (pus-like material), or whether it bulges on cut section. Examine the pelvis (where all the collecting tubules and blood vessels exit the kidney) for the presence of calcified kidney stones, parasites, tumors, cysts or other abnormalities.

URETERS:

In the pinniped, each ureter (the urine draining tube) exits the kidney medially and very near the caudal pole of the kidney (not medially and centrally as in terrestrial mammals). The left ureter is longer than the right ureter, simply because the distance from the left kidney to the bladder is greater than on the right. Palpate the entire distance of each ureter, from kidney to bladder, checking for patency or abnormalities such as pus and calcified stones, and take representative specimen samples for histopathology. Cut the ureters longitudinally, following them to, but not into the bladder.

BLADDER AND URETHRA:

In the pinniped, the bladder is a very small, highly muscular organ. It rarely will contain urine at post-mortem. If the bladder does appear to have urine in it, collect a sample of the urine using a sterile needle and syringe, and place the sample in a sterile red top tube for transport to a laboratory.

Once a urine sample, if present, has been collected, cut open the urinary bladder and note the presence of any stones, blood, pus, or bruising, hemorrhages, growths, nodules or diverticulae (outpouchings) in the bladder wall. Check to be certain that the two ureters enter the bladder symmetrically on either side of the bladder neck. The urethra should exit centrally and caudally from the bladder to course through to the vagina in the female or the prostate and penis in the male. Check the urethra for patency and any abnormalities such as strictures, tumors, or urethral stones.

REPRODUCTIVE ORGANS:

-- FEMALE

OVARIES AND OVIDUCTS:

Each of the two pinniped ovaries lie in a large, flattened pocket (or bursa) at the start of each oviduct. In the neonatal female pinniped, the ovaries are large, meaty and close to adult size, but without any obvious structural elements. In adult female pinnipeds, examine both the left and right ovaries and oviducts. Describe any structures present on either ovary, recording the exact number of each structure on both the right and left ovaries. Any fluid-filled, semi-transparent "cyst-like" structures may suggest to the clinician that the female pinniped was in a follicular phase of her reproductive (estrous) cycle. In addition, if there are hard, circular, whitish to yellowish "nodules", or white, somewhat circularly scarred areas, these might suggest how long ago and how many young that particular female has produced. Note the number, size, color, and consistency of each structure on each ovary.

Preservation of ovaries differs depending on the analyses to be performed. Histopathologic and life history ovarian specimens are removed intact and placed in a container of 10% formalin (see Appendix A). If ovaries are to be used for toxicologic analysis, they are removed, placed in a zip-loc bag and frozen at -20°C. Be certain to label the ovaries as left and right, and label the specimen package.

Each oviductal bursa lies near the start of each uterine horn. Trace each oviduct at its origin, where the ovary is, caudally to the uterus. Examine the bursae and report any swellings or constrictions.

UTERUS AND CERVIX:

In the normal neonatal (less than 7 days of age) female pinniped, the uterus is hypertrophic (large and fleshy). In all female pinnipeds, the uterus is bicornate (i.e. it has two large horns, rather than a large body, as in humans), and the two horns along almost their entire length are separated by a well-developed septum (sheet of tissue). Phocids have a long urogenital canal with a prominent fold of tissue (called the hymenal fold) at its most caudal aspect.

The cervix (where the uterus exits into the vagina) is a single canal in phocids. In otariids the cervix is double, that is, it has two channels that exit into the vagina.

In the adult female pinniped, be certain to cut open the uterus and cervix and note any foreign materials, such as fetuses, pus (infectious thick odiferous material), serum or blood, as well as any fibrous tissue, strictures, masses or other mechanical obstructions.

VAGINA AND VESTIBULE:

In the female pinniped, the vagina widens somewhat from where the cervix ends caudally toward the vestibule (the area just inside the external vulva). Examine the vagina and vestibule for tonicity, color, consistency and the presence of any growth or nodular structures.

-- MALE

TESTES AND VAS DEFERENS:

Externally, only testes of male otariids (sea lions and fur seals) can be found in a scrotal sac, and even in otariids this sac is often closely adhered to the body wall. All male phocid (true seals) and odobenid (walrus) testes are located in the inguinal area (groin), outside the abdomen, but deep under the skin and blubber, so as not to be visible externally.

Both the left and right testicles of the male pinniped should be examined. Note the relative abdominal or inguinal position, and measure the length and width of each testicle. Describe any structures on or under the surface capsule of each testis. Note blotchy, scarred, hemorrhagic, or other non-uniform areas if present.

Follow the vas deferens from each testicle down to the level of the prostate.

PROSTATE:

The prostate is not an easy organ to visualize in the male pinniped. It is often not only diffuse, but buried deeply and dorsally in the abdomen, just ventral to the pelvic bones and colon. It may be easiest to locate by following the short colon through the pelvic inlet. If this is impossible to do manually, the animal may have to be turned over (on to its ventral surface) and some of the pelvic bone removed dorsally to visualize the organ.

PENIS:

In the pinniped, the majority of the penis (except for the penile orifice at the skin surface) lies underneath the skin and firmly adhered to the ventral body surface. The penis is composed of a single, centrally located, blood-filled, sponge-like tissue, called the corpus cavernosum, which forms the bulk of the penis. The male pinniped, whether phocid or otariid, has an os penis (a long, thin triangular shaped bone) located centrally and longitudinally in the penis, alongside the urethra (which courses cranially at this point toward the urethral (penile) orifice); the os penis is situated halfway between where the penis originates at the ventral body wall and the penile orifice, where the urethra exits the body. Note any abrasions, lacerations, bruises, bleeding, scar tissue, growths or other penile abnormalities.

THE THORACIC CAVITY

The thoracic cavity in pinnipeds, when compared to terrestrial mammals, is very large. In general, the pinniped thoracic cavity extends caudally incorporating approximately 2/3rds of the animal's total body length. Presumably, the thoracic cavity has not yet been invaded during the necropsy procedure to this point. On opening the thorax, describe the relative positions of the organs, as well as any abnormalities or the presence and quantity of free fluid (blood, serum, pus) in the chest cavity.

DIAPHRAGM:

Examine the diaphragm from the cranial abdomen. Note that the diaphragm is an immense muscular structure that separates the thoracic cavity from the abdominal cavity. From the abdominal cavity, using a scalpel blade make approximately a 20 cm incision in the diaphragm, while observing the lungs. As the thoracic cavity is entered, the lungs (if they are healthy) should collapse, as the positive pressure from ambient air invades the air-proof chest cavity.

LUNGS AND BRONCHIOLAR LYMPH NODES:

(See under "The Pluck" on page 43)

RIBS:

The ribs are entirely cartilaginous and can be cut with sharp scissors or scalpel blade. If the ribcage needs to be opened, it may be easier in larger pinnipeds, such as male sea lions, to use pin cutters (used in orthopedic surgeries) or heavy-duty garden shears to cut the ribs, even though they are cartilaginous. Cut the ribs close to their dorsal attachments to the spine and remove the sternum and ventral rib cage.

THE NECK**THYROIDS AND PARATHYROIDS:**

The thyroids and parathyroids are located as paired structures adjacent to the ventral surface of the neck, just caudal to the laryngeal apparatus. The thyroid glands are often pinkish in color and plump in size and consistency. Parathyroids are smaller and firmer, with a slightly darker color. Make cross sectional slices through both the thyroid and parathyroid glands, noting consistency, texture, any discoloration, hemorrhage, nodules or exudate.

ESOPHAGUS:

As in terrestrial mammals, the esophagus runs longitudinally down the left side of the pinniped's neck. However, in the pinniped, the esophagus is very long and extremely distensible, in order to accommodate large fish that the animal may consume. Once the pluck is removed, longitudinally incise representative portions of the esophagus, and note any lesions or unusual occurrences.

MEDIASTINAL LYMPH NODES:

Mediastinal lymph nodes are located along the central midline in the cranial portion of the thoracic cavity. In pinnipeds, these lymph nodes, like those in the abdomen, are large, long, red and meaty. Cut representative cross sectional slices through these lymph nodes, noting any abnormalities.

THYMUS AND BROWN FAT:

The thymus and brown fat are present only in young pinnipeds. The thymus is a red and meaty structure found just inside the cranial thoracic cavity; the thymus lies over the heart just to the left of center midline. Note the size of the thymus.

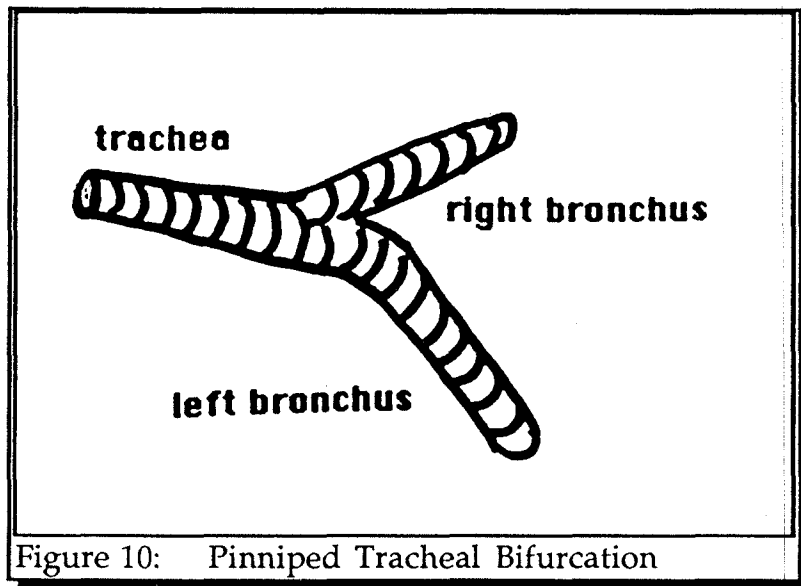
Brown fat is a dark yellow, thick, fatty tissue found in sheets subcutaneously over the back and the thoracic walls of the neonatal pinniped. Note the estimated quantity and location of the neonatal pinniped's brown fat.

Slice through both the thymus and brown fat, noting consistencies and any abnormalities.

THE PLUCK

The organs of the head and neck along with the lungs and heart can all be removed together. "The pluck", as this is called, is removed by peeling the skin off the ventral chin and neck. The muscles at the sides of the mouth are incised and the incision on each side is extended caudally to the level of the thorax, and the already exposed cut ribs. The tongue is grasped and pulled caudally; as this is done the connective tissue and muscle still attaching it to the sides of the carcass's neck are cut. The entire tongue, larynx, trachea, esophagus, bronchi, lungs and heart should come out as a unit for closer examination.

TRACHEA AND MAINSTEM BRONCHI: [Figure 10]



The trachea bifurcates cranially into two mainstem bronchi. In otariids, the trachea bifurcates more cranially than in phocids. The right bronchus branches off about 2 cm cranial to the left bronchus. Both bronchi in their entirety are very wide in diameter and short in length. In all pinnipeds, except the walrus, the trachea, bronchi and large bronchioles all contain cartilaginous rings; these rings are incomplete and C-shaped, except in the walrus, where the cartilaginous rings are complete. In otariids, but not in phocids, the cartilaginous rings even extend down the bronchioles into the terminal airways (the alveoli). Using scissors, cut longitudinally down the trachea and each of the mainstem bronchi, noting any foreign bodies, bruising, hemorrhage, parasites (such as lungworms), exudate, tumors or other abnormalities.

LUNGS AND BRONCHIOLAR LYMPH NODES:

The lungs in pinnipeds occupy the majority of the thoracic cavity. On opening the chest cavity, the lungs should appear pink in color. On cut surface, there should be air in the bronchioles and bronchi. Healthy lung tissue placed in water or formalin, should float. Make multiple cuts in the lung tissue, looking for any parasites, mucus production, pus, blood or other abnormal materials. Scraping the cut surface of the lung often assists in locating lesions and parasites.

The bronchiolar lymph nodes, 2 to 4 in number, can be found just cranial to the heart base adjacent to the aortic arch and pulmonary artery. Incise cross sectionally noting any abnormalities.

HEART:

The heart of the pinniped is similar to that of a terrestrial mammal, except that it is often larger, relative to the animal's size. The pericardium is an opaque sac in which the heart rests; this sac is thick walled, and may contain a small amount of clear, straw-colored fluid. If the pericardial wall is excessively thickened or there is increased fluid accumulation, measure the quantity, assess the quality and aseptically take a representative sample and place it in a sterile red top tube. In pinnipeds, the myocardium and endocardium (the heart muscle and lining) are thicker than in most terrestrial mammals, and are a deep, dark red color.

Heart dissection in pinnipeds, just as in other mammals, follows the natural physiologic flow of blood, moving from pulmonary vein, to right heart, to lungs, to left heart to aorta. To dissect the heart, remove the organ at its attachment points to the pulmonary vein, pulmonary arteries, and aorta. Hold the heart left (thick) side down in the palm of your hand, with the base (the top) of the heart toward the palm of your hand and the apex (the pointed end) toward your fingertips. Cut into the pulmonary vein and enter the right atrium. Look at the first of four heart valves, the tricuspid valve, which separates the right atrium from the right ventricle; the valve should be opaque, strong, but highly flexible, and of equal density and smooth in texture throughout. In this and all successive valves, note any nodules, irregularities or thickened areas.

Cut into the right ventricle; note any lesions or unusual structures. Cut up through the pulmonary artery (a rather flappy blood vessel that leaves the right ventricle at its cranial aspect), noting the pulmonic valve. Next open the left atrium from the incoming pulmonary artery; the left atrial wall should be thicker and more muscular than the right side of the heart. Note the mitral valve between the left atrium and left ventricle. Enter the left ventricle, which is the thickest-walled of all the chambers of the heart; note any lesions or unusual structures. Examine the walls between the right and left atria and right and left ventricles for any signs of non-valvular or non-vascular openings between them (these can be congenital or hereditary defects, or fetal structures meant to close at birth). The aortic valve separates the left ventricle from the aorta. The aorta is the most muscular artery in the body. Cut through it longitudinally as it exits the heart and examine its intimal surface lining for any lesions or unusual structures.

As mentioned above, there are four valves in the heart. These are strong, but highly flexible, films of tissue, separating the atria from the ventricles and the heart from the lungs and aorta. The blood flows into the heart from the pulmonary vein at the right atrium, through the tricuspid valve to the right ventricle, to the lungs via the pulmonary artery, from the lungs through the pulmonic valve in the left atrium, from the left atrium to the left ventricle via the mitral valve and from the left ventricle into the aorta through the aortic valve. The thickest muscular tissue

is in the left ventricle; the thickest-walled artery is the aorta. The most flaccid tissue is in the right atrium, and the most flaccid vein the right pulmonary vein.

THE NERVOUS SYSTEM

In pinnipeds, the central nervous system (CNS) is composed of the brain and spinal cord, both of which lie within bony structures (the skull and spinal (vertebral) column). If possible, the brain and spinal cord should be examined on every pinniped undergoing necropsy (not those simply exhibiting neurologic signs). Before beginning an examination of the CNS, verify any needs for voucher specimens.

The CNS should be removed carefully for closer examination¹⁶. It is important to realize that the CNS nervous tissue is very fragile, and must be handled carefully, or it will macerate and disintegrate in your hands.

1. Cut away and remove the skin, blubber, muscle and connective tissue overlying the entire dorsal spine and caudal skull area;
2. Starting caudally, using a Stryker oscillating saw or cast cutter, longitudinally cut two lines the entire length of the spinal column into the vertebral bodies equidistant (~1 inch to either side) from the animal's dorsal midline.
3. Lift the tops (dorsal bony covering) off each vertebral body in the spinal column exposing the spinal cord beneath.
4. Move to the base of the skull and again, using a Stryker saw or cast cutter, prepare to remove the calvarium (dome-like bony structure that overlies the brain). Use of the following three cuts will preserve the skull's bony structure for additional life history information.

Make two symmetrical cuts on each side of the caudal aspect of the skull running from each occipital condyle to the foramen magnum.

Make a third cut perpendicular to the first two cuts transversely across the frontal bone just posterior to the supraorbital process.

5. Gently, lift the calvarium off of the brain, gingerly cutting away the brain's connective tissue attachments to the inside of the skull with scissors.
6. Turn the head upside down to allow gravity to assist in gently teasing the brain out of the skull. The cranial nerves and connective tissue meninges will have to be severed, but then the brain should gently fall onto the table.

7. Once the brain is out, working from the caudal aspect of the spinal column, gently tease the spinal cord out of the vertebral column. You will need to cut peripheral nerves and connective tissue to do this, but once you have, you should have the entire CNS on the necropsy table in front of you.

For ease of viewing you may wish to remove the head prior to brain removal. The spinal cord will have to be severed in this process so the entire CNS will not be removed intact. Nevertheless to disarticulate the head from the body, at the level just caudal to the occipital protuberances make a deep transverse cut down to the atlanto-occipital joint (between the skull and the first cervical vertebra), twist and disarticulate the skull from the spine.

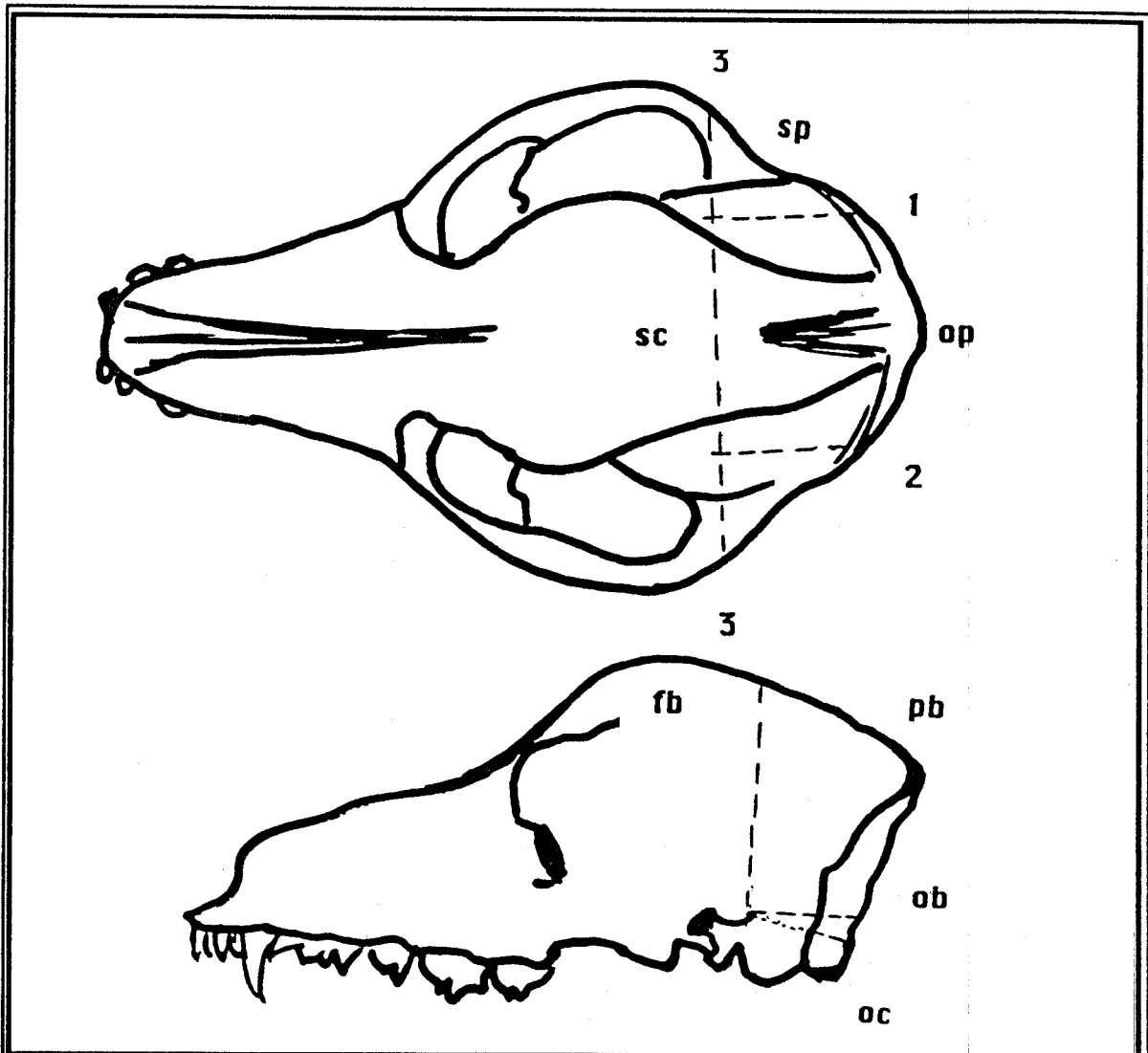


Figure 11: The Skull Locations to Cut for Removal of the Brain

KEY:

- oc = occipital condyle
- ob = occipital bone
- op = occipital protuberance
- fb = frontal bone
- sc = sagittal crest
- pb = parietal bone
- sp = supraorbital process

The cerebrum is the massive, most cranial portion of the brain. The cerebellum is caudal to the cerebrum and sits dorsal to the brainstem. The brainstem is at the most caudal aspect of the brain, where the majority of the cranial nerves originate, and tapers as it moves caudally toward the spinal cord at the first cervical vertebra. Examine each structure for symmetry, consistency in color, texture and density, and note any bruising, discoloration, constricted or swollen areas, masses, exudates or any other abnormalities. Pay particular attention to the pituitary gland found protruding from the ventral midline of the brain at the most cranial aspect of the brainstem [Figure 12].

Make cross sectional slices through the brain and spinal cord in a "bread loafing" pattern.

Peripheral nervous system tissues are not normally examined during necropsy. If there is a necessity to do so, peripheral nerves are most often located coursing alongside major veins and arteries.

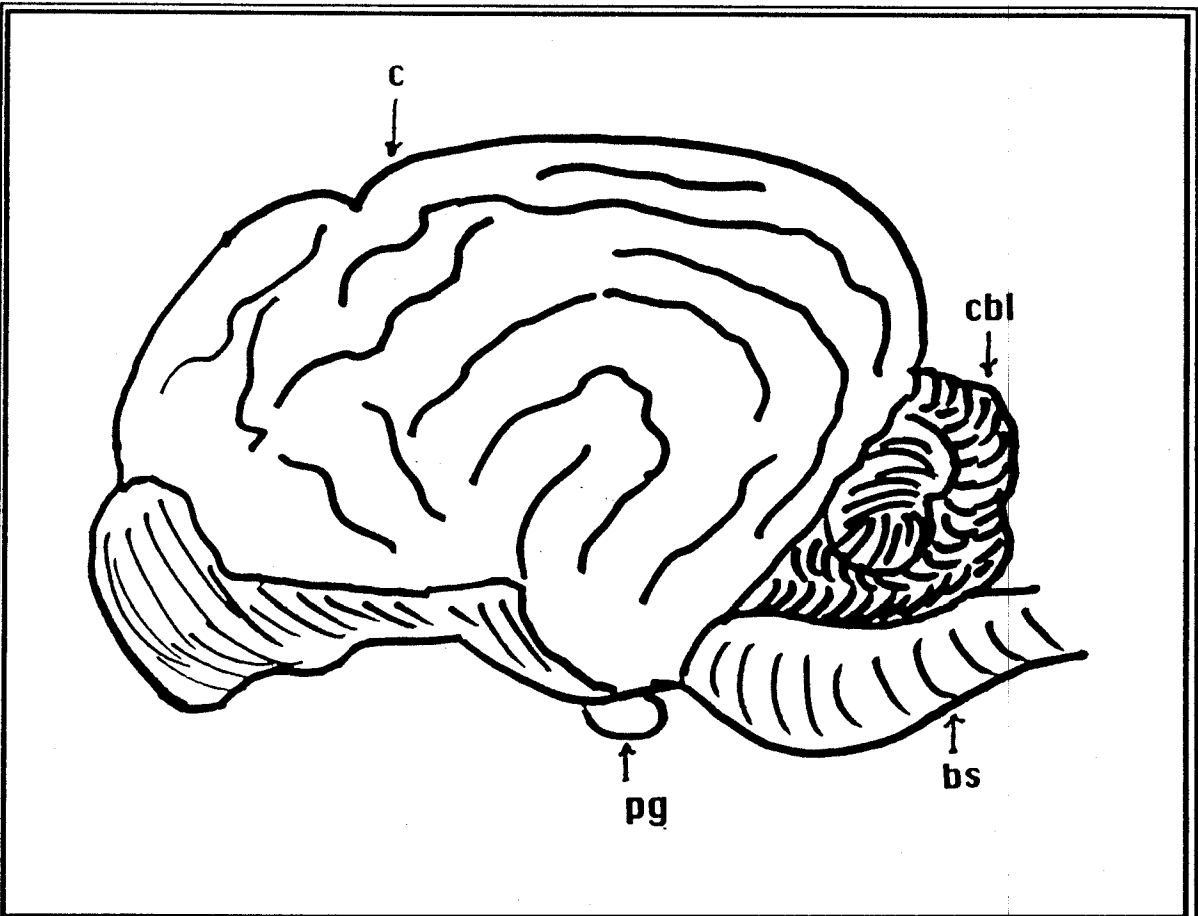


Figure 12: Major Anatomical Divisions of the Brain

=====

KEY:

- c = cerebrum
- cbl = cerebellum
- bs = brainstem
- pg = pituitary gland

COLLECTION, PREPARATION AND PRESERVATION OF TISSUES AND SPECIMENS

HISTOPATHOLOGY

ADDITIONAL EQUIPMENT RECOMMENDED:

Sharp knife or scalpel blade
Dissecting tray or cutting board
Screw top plastic specimen containers containing 10% formalin

COLLECTION AND PREPARATION OF TISSUES:

Tissues for histopathology should be obtained with as sharp an instrument as possible, preferably a necropsy knife or scalpel blade. In all cases, avoid blunt or crushing trauma to the tissues being collected. In areas of observable lesions, be certain to take normal as well as abnormal tissue for histopathologic analysis.

The optimal size tissue sample to yield the best fixation is one approximately 1 cm³, although samples as large as 2 cm² by 0.5 cm are acceptable if adequate fixative volume is provided. The container of choice for histopathological specimens is plastic, but glass will suffice; the container must have a water-tight screw-top closure. Label the specimen jar with an indelible pen, or label the actual specimen directly by inserting a Tyvek tag, labeled in pencil, directly into the formalin with the specimen.

If a fetus, with its attendant placental material, is present, take, as aseptically as possible, portions of both the fetus and the placenta. Divide these into two sets of tissue samples; refrigerate one set, and place the other in 10% neutral buffered formalin. Immediately contact the laboratory. Maternal blood and/or urine (10 ml of each, if available), and fetal fluids, including stomach contents (whatever is present), should also be collected and refrigerated.

PRESERVATION OF TISSUES:

Standard preservation of tissues and specimens for histopathology is done by placing 1 cm³ sections in a container of 10% neutral buffered formalin (See Appendix A). For adequate fixation, the ratio (by volume) of formalin in the container to tissues placed in it must be at least 10:1, i.e. 10 parts formalin to 1 part tissue. Follow this ratio religiously, because without adequate fixation (caused by too large a tissue size or too small a fixative volume) valuable histopathologic information will be lost.

CHECKLIST OF HISTOPATHOLOGIC SPECIMENS:

This form must accompany any tissues sent for histopathology.

<u>Specimen Checklist for Histopathology</u>		
Id No. _____	Time/Date _____	Path Tech _____
Blubber Thickness = _____ cm	Other Comments:	
<input type="checkbox"/> Stomach	<input type="checkbox"/> Diaphragm	<input type="checkbox"/> Bone Marrow
<input type="checkbox"/> Duodenum	<input type="checkbox"/> Rib	<input type="checkbox"/> Eye, left
<input type="checkbox"/> Jejunum	<input type="checkbox"/> Thyroid	<input type="checkbox"/> Eye, right
<input type="checkbox"/> Ileum	weight = _____g	<input type="checkbox"/> L.N., Peripheral
<input type="checkbox"/> Colon	<input type="checkbox"/> Parathyroid, left	specify _____
<input type="checkbox"/> Mesenteric L.N.	weight = _____g	<input type="checkbox"/> L.N., Other
<input type="checkbox"/> Pancreas	<input type="checkbox"/> Parathyroid, rt	specify _____
<input type="checkbox"/> Spleen	weight = _____g	<input type="checkbox"/> Mammary Gland
<input type="checkbox"/> Liver	<input type="checkbox"/> Esophagus	<input type="checkbox"/> Skeletal Muscle
weight = _____g	<input type="checkbox"/> Mediastinal L.N.	<input type="checkbox"/> Skin
<input type="checkbox"/> Gall Bladder	<input type="checkbox"/> Thymus	<input type="checkbox"/> Tongue
<input type="checkbox"/> Adrenal, left	<input type="checkbox"/> Brown Fat	<input type="checkbox"/> Tonsils
weight = _____g	<input type="checkbox"/> Trachea	
<input type="checkbox"/> Adrenal, right	<input type="checkbox"/> Bronchus	Add'l Specimens
weight = _____g	<input type="checkbox"/> Lung, left	_____
<input type="checkbox"/> Kidney, left	<input type="checkbox"/> Lung, right	_____
weight = _____g	<input type="checkbox"/> Heart	_____
<input type="checkbox"/> Kidney, right	weight = _____g	_____
weight = _____g	<input type="checkbox"/> Pulmonary Vein	_____
<input type="checkbox"/> Urinary Bladder	<input type="checkbox"/> Right Atrium	_____
<input type="checkbox"/> Ovary, right	<input type="checkbox"/> Tricuspid Valve	_____
weight = _____g	<input type="checkbox"/> Right Ventricle	_____
<input type="checkbox"/> Ovary, left	<input type="checkbox"/> Pulmonic Valve	_____
weight = _____g	<input type="checkbox"/> Pulmon. Artery	_____
<input type="checkbox"/> Testis, right	<input type="checkbox"/> Left Atrium	_____
weight = _____g	<input type="checkbox"/> Mitral Valve	_____
<input type="checkbox"/> Testis, left	<input type="checkbox"/> Left Ventricle	_____
weight = _____g	<input type="checkbox"/> Papillary Muscle	_____
<input type="checkbox"/> Uterus	<input type="checkbox"/> Aortic Valve	_____
<input type="checkbox"/> Cervix	<input type="checkbox"/> Aorta	_____
<input type="checkbox"/> Vagina	<input type="checkbox"/> Brain	_____
<input type="checkbox"/> Prostate	weight = _____g	_____
<input type="checkbox"/> Penis	<input type="checkbox"/> Pituitary	_____
	weight = _____g	_____
	<input type="checkbox"/> Spinal Cord	_____

PARASITOLOGY¹⁷

ADDITIONAL EQUIPMENT RECOMMENDED:

Large and small fecal collection wands
 Glass microscope slides and coverslips
 Containers with 10% formalin
 Forceps

If the parasite must be sent to a parasitologist for identification--

Commercial fecal floatation set-up
 Physiological saline
 Petri dishes
 Warm 70% ethanol
 Phenol
 Absolute alcohol
 AFA
 Solution of 2.5% potassium dichromate

COLLECTION, PREPARATION AND PRESERVATION OF TISSUES:

The study of parasites, even though many may be observed while examining a pinniped, is still a very specialized field. For routine fecal floatation on-site, collect 4-5 grams of feces from the terminal colon. If any delay in examination or preparation is anticipated, the sample should be placed under refrigeration (4° C). Except for hookworm eggs, which deteriorate rapidly, most parasite eggs can remain identifiable for days if the fecal sample is kept refrigerated¹⁸. In the case of coccidial organisms, place 1 part feces in 5 parts of potassium chromate in a jar and package for shipping.

To prepare a blood specimen for parasitological examination, collect 1 ml of blood. Place one drop on a clean, glass microscope slide. Place the rest in a red top tube and add 9 ml of 10% neutral buffered formalin. All parasites, whether from feces or blood, if fixed in-house, should be mounted on microscope slides using piccolyte sealant under the coverslip as the mounting media. Label all specimens.

It is not unusual for the layperson, volunteer, technician or veterinarian to be unable to identify the genus and/or species of a parasite being collected. If a fecal sample is to be sent for parasitological examination, collect 5-10 grams of feces and place in a container with 10% neutral buffered formalin at a ratio of 3:1 formalin:feces.

For preparation of an individual parasite specimen, if the parasite is particularly dirty, first gently wash it with a syringe-full of physiological saline. Then, collect the parasite and the tissue to which it may be attached, and place it in a jar containing a 9:1 solution of 10% formalin:tissue, applying a tightly fitting lid.

For clearing nematodes, briefly place the parasite in a petri dish containing warm 70% ethanol, until the specimen relaxes and stretches out straight. Next flood with a 4:1 mixture of phenol:absolute alcohol, and leave the petri dish uncovered in a dust-free area until all the liquid has evaporated. Store the specimen in 70% ethyl alcohol.

For clearing cestodes or trematodes, place the individual parasite (if it can be isolated) in a petri dish of physiologic saline in the refrigerator (4° C) for 2 hours to relax the specimen and allow it to release any eggs if present. Once the parasite is relaxed, take a teasing needle and gently straighten out the parasite. Preserve it and its eggs, if present, by slowly flooding the petri dish with a hot (42-52° C) solution of AFA (see Appendix A); allow it to sit for a minimum of 1-2 hours (overnight is optimal). Store the specimen in 70% ethyl alcohol.

Label the specimen, including the host animal's (pinniped's) species, age and sex. Note where the parasite was located, and any gross pathological changes associated with it, and include this information with the specimen.

BACTERIOLOGY¹⁹

ADDITIONAL EQUIPMENT RECOMMENDED:

- Sterile surgical gloves in appropriate sizes
- Alcohol lamp or Bunsen burner and matches/lighter
- New, sterile #15 and #10 scalpel blades with handle
- Sterile swabs or culturettesf
- Sterile red top tubes
- Refrigeration

COLLECTION AND PREPARATION OF TISSUES:

If bacterial disease is suspected, because motile intestinal bacteria can seed to many organs within 5 to 10 minutes after death, it is best to minimize contamination of the sample by collecting bacterial samples as soon as the carcass's abdomen or thorax is opened⁸.

It is essential that material to be cultured for bacteria be collected in a sterile manner. First, check to make certain there are no flammable chemicals in your work area. Then, light the alcohol/Bunsen burner. Heat your #15 (sterile, sharp-tipped) scalpel blade in the flame for approximately 15 seconds. Immediately make a stab incision into the organ you wish to culture. The hot blade will singe the tissue, killing any organisms present on the tissue's surface. Taking precautions not to contaminate (with hands, coughing, non-sterile instruments) the area of interest, carefully insert a sterile swab or culturette into the stab incision. Gently roll the swab or culturette around inside the incision. Carefully remove the swab and immediately place it (without touching anything, including the outside of your transport container) in a sterile container. The sterile container may be one provided by your laboratory, one supplied with the culturette, or a sterile red top tube ordinarily used for blood collection.

If pus (purulent liquid material) is present, using a sterile syringe, collect the material leaving no air bubbles in the syringe. This will allow for culture of potential anaerobic (non-oxygen needing) bacteria at the laboratory.

If a bacterial infection is suspected in a solid organ, such as the liver, kidney or lung, sterilize your scalpel blade in the alcohol/Bunsen burner flame, and cut a wedge of tissue, approximately 2 to 4 cm square, which includes the suspect area, and place the sample in a Whirl-Pak bag or a red top tube. If an intestinal bacterial infection is suspected, use string to tie off both ends of a small section (about 2 cm) of intestine, cut each side of the section beyond the tie-off pointed and place the tube-like specimen in a Whirl-Pak bag. If a brain infection is suspected, as aseptically as possible, remove the skull with a Stryker saw or rongeurs, and aseptically take a 3 cm² piece, placing it directly in a Whirl-Pak bag or sterile red-topped tube. Label any specimen collected.

PRESERVATION:

Any bacteriological sample must be stored under refrigeration (DO NOT Freeze). Immediately request a laboratory pick-up or personally before the end of the day, take the material to the laboratory yourself. Never allow a bacteriological sample to sit overnight unattended! It is best to allow the laboratory the opportunity to plate the bacterial sample within 4-6 hours, since some bacteria will die if left overnight at 4° C.

In general, the size, location and preparation of specimens to be submitted²⁴ for biotoxicologic examination are as follows:

Stomach contents: ~1/2 frozen (-20° C)
 ~1/2 refrigerated (4° C)
 ~10 grams in equal volume of 10%
 buffered formalin (for algal identification)²⁵

Liver:	100 grams	Left caudal lobe	Frozen
Kidney:	100 grams	Left caudal pole	Frozen
Blubber:	100 grams	Ventral Midline	Frozen

(just cranial to the xiphoid process)

Place each of these specimens in a clean, plastic container, with a tight fitting top. If the animal's size or carcass condition precludes specimens of the recommended size above, take whatever is available.

Toxic algal bloom material is most often found in stomach contents, whether free or incorporated into food materials, such as fish. So stomach contents are the most valuable material for diagnosis of biointoxication; accompanying samples of liver, kidney and blubber may be helpful to the toxicologist in correlating data. Even if biotoxins are strong suspects, always send in tissues for histopathology as well, and be certain to inform the toxicologist that histopathology is pending.

Liver, kidney and blubber once collected, should be frozen at -20° C, in a standard walk-in or chest freezer. The freezer should not be "frost-free", as is found in refrigerator-freezer combinations and some chest freezers, because some toxins are sensitive to degradation by the constant freeze-thaw cycles that materials in a frost-free freezer undergo.

HEAVY METALS AND ANTHROPOGENIC (man-made) ORGANICS:

ADDITIONAL EQUIPMENT RECOMMENDED

Teflon sheeting (for clean working surface)
 Teflon jars with lid labels (if unavailable, acid rinsed glass jars covered with plastic film prior to replacing lid for heavy metals and acetone rinsed jars covered with acetone rinsed aluminum foil prior to replacing the lid for organics)
 Stainless steel knives
 Titanium knife with Teflon handle
 High grade ethanol and distilled water for rinsing knives
 Whirl-pak or zip-lok plastic bags (for heavy metal specimens)
 Heavy duty aluminum foil (for organic specimens)

COLLECTION AND PREPARATION OF TISSUES

Because of the possibility that presence of contaminants may lead to litigation and because analyses may involve detecting extremely small amounts of contaminants, utmost care must be taken in the collection and processing of tissues. The chain-of-custody procedures detailed under Shipping of Tissues and Specimens should be followed. Ideally, specimens should be collected under conditions that avoid contamination. Avoid salt water, tobacco smoke, vehicle exhausts, bug sprays and other aerosolized foreign materials during collection. Recognizing that a laboratory and special materials such as Teflon containers and titanium knives are not always available, if care is taken, specimens can be collected with ethanol-rinsed stainless steel instruments and subsampled by the laboratory performing the analyses.

The tissues and other specimens routinely collected from pinnipeds for toxicant analyses are blubber, liver, kidney, brain; and for special considerations, urine, stomach contents, blood serum, whole blood, reproductive organs, milk, and feces. The size of specimens to be collected, if available, is:

Blubber	300 grams
Liver	300 grams
Kidney	300 grams
Brain	300 grams
Urine	500 ml.
Stomach contents	500 ml.
Serum	50 ml. (in red top tube)
Whole blood	50 ml. (in purple top tube)
Milk	50 ml. (in red top tube)

It is important that toxicological findings are correlated with general signs and lesions. Therefore, gross necropsy reports should accompany any specimens, and histopathological results, if any, should be received as soon as they are completed.

General:

Tissue samples are to be collected as rapidly as possible after opening body cavity in order to prevent contamination and deterioration.

Stainless steel knives should be used to make initial opening of the body cavity. (Do not use titanium knives to cut through skin since this dulls the knife. Only use them for collecting the actual specimen material).

Blades should be rinsed with ethanol before a tissue sample is taken. Because ethanol will fix blood on a metal surface, blades should be rinsed with distilled water first and then ethanol after each sample is taken and before a new sample is collected.

Except where indicated above, specimens should be placed in Teflon bags or containers. If such containers are not available, the specimen should be divided and placed into separate containers for heavy metals or organics (See Additional Equipment Recommended). If the appropriate containers are not available, the specimens should be divided and wrapped in plastic wrap (for heavy metals) or heavy duty aluminum foil (for organics).

All specimens (except whole blood) should be frozen immediately after collection. Ideally, each sample should be frozen by immersion in liquid nitrogen for 10 minutes or frozen at -70°C or lower. If such super-cold equipment is not available, samples should be frozen at -20°C . At a minimum, refrigeration is required until a dry ice source or freezer (home chest freezer or walk-in freezer only) can be located. A refrigerator's freezer is not adequate for long-term storage. Freezing to very low temperatures is not necessary for tissues awaiting heavy metal analysis.

Individual Tissues--Instructions

Blubber

Collect on ventral midline just cranial to the xiphoid process.

Separate blubber from underlying muscle layer and skin.

Wash tissue in high grade distilled water to remove blood and other fluid before freezing.

Liver

Collect 150-200 gram section from each side of the liver at the distal lobes on their medial aspect. Wash tissue in high grade distilled water to remove blood and other fluid before freezing.

Kidney

Collect from left caudal pole.

Wash tissue in high grade distilled water to remove blood and other fluid before freezing.

Brain

Halve longitudinally.

Whole Blood

Should not be frozen. Refrigerate for immediate analysis.

SHIPPING AND LABORATORY ANALYTICAL TECHNIQUES

If a liquid nitrogen shipper is available, it should be used. The liquid nitrogen shipper should be filled with liquid nitrogen for at least six hours to fully prepare it for shipping. Pour off excess liquid nitrogen and place the frozen samples in the shipper.

If a liquid nitrogen shipper is not available, specimens should be shipped under conditions to avoid thawing. Specimens should be placed in an insulated container with an adequate amount of dry ice to prevent thawing.

Whenever a shipment is made, the receiving laboratory should be notified in advance of shipment. Unless special arrangements are made, specimens should not be shipped over a weekend. Documentation describing the animal, gross necropsy results, and other information should be included.

Under certain circumstances, e.g., during an unusual mortality event, individuals may be given specific instructions as to which laboratories should perform analyses and what analyses should be performed. If analyses are being conducted for an independent investigator, the laboratory must be given specific instructions on the type of analyses to be performed. A statement such as "analyze for toxic substances" is entirely inadequate.

It is essential to check with the toxicology laboratory to be certain that it is capable of conducting the test(s) desired. Make certain that the laboratory chosen is staffed by professional analytical chemists, pathologists, and technicians, regularly trained and up-to-date in the use of modern instrumentation and the sophisticated techniques toxicological analyses required.

Laboratory analytical methods are continually being changed and improved. Laboratories should have documentation of proper validation, including standards curves for standard reference materials (SRMs), revalidation of analytical methods (standard operating procedures), documentation of method accuracy and precision, and a quality assurance program.

Such validation allows a greater degree of standardization and interlaboratory reliability. In addition, it is important to realize that every chemical analysis performed in a laboratory has both a limit of detection and a (higher) limit of reliable quantification associated with it. The researcher or clinician should know what these limits are, not only for the compound itself, but also for the matrix within which the compound exists, e.g., liver, blubber, etc. A toxicology report from a laboratory of "not present in detectable amounts" is generally appropriate, whereas a report of "not present" is generally inappropriate. Levels of detection must be given for the compound.

The laboratory must have a written protocol in place for each assay, as well as documented quality control procedures, not only of analytical techniques and methods, but also for personnel performing analyses. If there is any suspicion that the data from materials you are sending to a laboratory for analysis will be needed in a court of law, be certain the laboratory's personnel are trained and regularly updated regarding instrumentation and procedures for which they have responsibility. Make certain that the laboratory records processing errors, equipment failures, or quality control standards outside the norm. These are the most reliable ways to prove that a laboratory is scientifically credible.

In cooperation with the National Marine Fisheries Service, the National Institute of Standards and Technology has a marine mammal quality assurance program in place that allows for interlaboratory comparative exercises, standardized calibrations, and the provision of SRMs. The American Association of Veterinary Laboratory Diagnosticians (AAVLD) and the College of American Pathologists (CAP) also accredit many private and public laboratories in the United States.

It is also helpful to choose a laboratory which has rapid reporting, by telephone or FAX, followed by transmission of original documentation by mail. Data received from a laboratory regarding any test performed on tissues from an animal must be kept in that animal's permanent case record folder. If it is anticipated that litigation may be involved, the case folders and all specimens from the case must be kept under lock and key, and a strict chain of custody kept on the records.

MISCELLANEOUS DIAGNOSTIC SPECIMENS

Always be certain prior to proceeding that you contact the diagnostic or research laboratory of choice to insure that appropriate personnel, equipment and supplies are on hand for performing the special test analysis you are requesting.

ISOENZYMES:²⁶

Isozyme studies require the collection of blood or tissue. Collect whole blood in sodium citrate (blue top tube), centrifuge for 10 minutes at 10,000 rpms, draw the plasma off the top of the tube and send on ice immediately or freeze until sent to the laboratory. A minimum of 10 to 100 grams of muscle tissue can also be aseptically collected and refrigerated or placed on ice to await immediate shipment to the laboratory.

CYTOCHROME P-450:²⁷

Tissues should be as fresh as possible, preferably collected within 30 minutes following death, since they will be used for analyses of halogenated and polynuclear aromatic hydrocarbons. Liver, lung, heart, kidney, small intestine, and skin samples of 100 grams each may be collected. Tissues should be divided into 10 gram allotments, each folded into a piece of aluminum foiled and labeled inside and out. These samples are then frozen, preferably in liquid nitrogen, or placed on dry ice for immediate transport to the laboratory of choice. Be certain to call the laboratory ahead of time to inform them of the pending shipment.

DNA STUDIES:²⁸

Blood in the live pinniped, or heart muscle, skin, sperm or skeletal muscle from the freshly dead pinniped, are adequate to perform DNA isolation. In the live animal, collect a minimum of 10 ml of blood in an EDTA (purple top) or sodium citrate (blue top) tube. Once collected, place in a refrigerator (at 4° C) or on ice for pick up by the laboratory. If the blood must wait for pick up, it is best to centrifuge it for 5 minutes, then perform two steps: (1) decant (pour or draw off) the straw colored plasma, label it and freeze it, and (2) pipette off the buffy coat (1 to 3 mm whitish layer between the red blood cells and plasma), place it in a separate vial, and label and freeze it. Refrigerate (DO NOT FREEZE) the red blood cells. Label the specimen and contact the laboratory.

In the freshly dead pinniped, collect heart or skeletal muscle, skin, gonadal tissue, or sperm. The tissue sample size to take is approximately 2 to 10 grams; this material should be sliced with a sharp, clean knife or scalpel blade into 1 cm thick sections prior to fixing. To fix, either freeze at -20 to -70° C, or preserve in 70% ethanol or isopropyl alcohol.

TOOTH/BONE/SKELETAL PREPARATION

ADDITIONAL EQUIPMENT RECOMMENDED:

Nylon mesh bag
 Large barrel
 or
 3 foot deep hole in the ground
 or
 flesh-eating beetles
 Trisodium phosphate
 Large pot
 Stove

COLLECTION AND PREPARATION OF SKELETAL REMAINS:

Once necropsy examination is complete, if the skeleton is needed for natural history studies, remove as much skeletal muscle as is possible from the skeleton and place it in a mesh bag. Either bury the bag at least 3 feet under the soil surface for 4 weeks, or place in shallow ocean (attached to a point on shore) for 2 to 5 days.

Other methods involve placing the skeleton in a specially prepared 50 gallon drum containing flesh-cleaning beetles for up to 4 weeks. Alternatively, the bone, may be placed in a detergent solution for approximately two weeks to de-grease it, followed by a weak ammonium hydroxide solution for 1-2 days maximum (to bleach the bones)²⁹. Once cleaned, bony materials can be frozen, placed in formalin, or air-dried, depending on their intended use.

TOOTH PREPARATION FOR AGING PINNIPEDS:

In order to age a pinniped, the best method is to extract a canine tooth from the upper jaw. In the field, the tooth, once collected, can be refrigerated, frozen or packed in salt³⁰. At an institution, boil the tooth in a solution of trisodium phosphate (diluted at 1 Tablespoon/quart of water) for approximately 15 minutes to remove the pulp. Then air dry the tooth. Once dry, using a high intensity light and hand lens (or a dissecting microscope), the horizontal growth rings of the tooth can be counted. A pair of rings (one "light" and one "dark") equals 1 year of age. Some institutions cut the tooth longitudinally for more ease in counting rings.

SHIPPING/TRANSPORT

PACKING MATERIALS:

Each specimen's container should be clearly labeled with indelible ink, including date collected, species, sex, identification number, source of tissue/body fluid, and the collector's name or institution. If being shipped for analysis, the tissues should be accompanied by a copy of the gross necropsy report. If a number of specimens are to be shipped in the same package, label the package inside and out with your name and address (the sender) and the name and address (the receiver) to which the package is being shipped.

Prepare a form in quadruplicate [See Appendix C] listing each specimen, the date collected, species, sex, identification number, source of tissue/body fluid and to whom the specimen is being shipped. Enclose one copy inside the package, place one in an envelope addressed specifically to the laboratory of choice and attached firmly to the outside of the shipping container, send one form with your monthly report to your Regional National Marine Fisheries Service Office, and keep one on file, attached to the necropsy report at your facility. Use smear-proof ink to insure legibility.

Each time a tissue sample or specimen leaves your facility, it must be accompanied by its own signed Chain of Custody Form [See Appendix D]. Sign next to the same printed name and include the Form with the specimen. Each person who handles the sample for whatever reason must sign and date the form as noted above.

Samples should be tightly packed to avoid jostling, breakage, or thawing during shipment; newspaper or butcher paper assists in insulation during shipping. Shipping of medical diagnostic specimens by air or mail is subject to Federal regulations. Rules require proper packaging, including securely sealing the package, adding sufficient absorbent materials to take up the contents in case of leakage, and including shock resistant material to withstand ordinary handling during transit³¹. The outside of the package should be labeled with "DIAGNOSTIC SPECIMEN" written in large identifiable letters.

The importance of communication between the sender and receiver cannot be overemphasized, particularly if the specimens being shipped are valuable biological and/or legal samples.

SHIPMENT OF CLINICAL PATHOLOGICAL SPECIMENS:

Shipment of blood and bodily fluids collected from live (or very recently dead) pinnipeds, must be shipped to the laboratory as quickly as possible following collection. Have a carrier or courier service pick up and deliver the specimens to the laboratory or airport; if possible, do this yourself or direct a responsible person to do this for you. Emphasize the importance of rapid delivery of samples. For transport via air or over long distances, samples should be kept cool, by packaging them in a styrofoam container. Serum can be shipped frozen and packed on dry ice.

SHIPMENT OF HISTOLOGICAL SPECIMENS:

Histopathological specimens for shipment should be well-sealed (a piece of packing tape around the container's screw top will help prevent leakage). If large numbers of tissues must be shipped, tissues in 10:1 formalin:tissue, once entirely fixed (3-4 days), may be removed and placed in smaller amounts of 10% buffered formalin for shipping purposes.

SHIPMENT OF MICROBIOLOGICAL SPECIMENS:

Bacteriological and mycological specimens should be kept chilled during transport; ship in styrofoam containers and include at least two or three blue-ice or similar frozen gel packs. If transportation time is expected to be longer than 24 hours, the samples must be packed in dry ice. Viral specimens must be frozen; frozen specimens should be maintained while being shipped by using an insulated container made of styrofoam and packed with dry ice. Make certain the styrofoam container is well-sealed with packing tape to keep the cold in during transport.

SHIPMENT OF PARASITOLOGICAL SPECIMENS:

It is best to keep parasitological specimens cool during shipment. Double bag, or seal screw top containers with packing tape, to prevent leakage, and ship in styrofoam containers if possible.

SHIPMENT OF TOXICOLOGICAL SPECIMENS:

Toxicological specimens must be shipped frozen. Place them in styrofoam containers with either dry ice or multiple frozen gel packs. Make certain the styrofoam container is well-sealed with packing tape and/or enclosed in a cardboard packing box to keep the cold in.

CONCLUSIONS

The importance of history, findings, and lesions must not be underestimated in shipping specimens to a diagnostic laboratory. Such information (such as a complete history, a good description of signs, and an accurate description of gross lesions) is invaluable, not only to the clinician or diagnostician, who must intelligently choose appropriate tests to be run by the laboratory, but also to the laboratory itself, which must determine the diagnostic methodology to be used and the significance of pertinent results. Each of these steps is a piece of the puzzle, a final diagnosis [Figure 13].

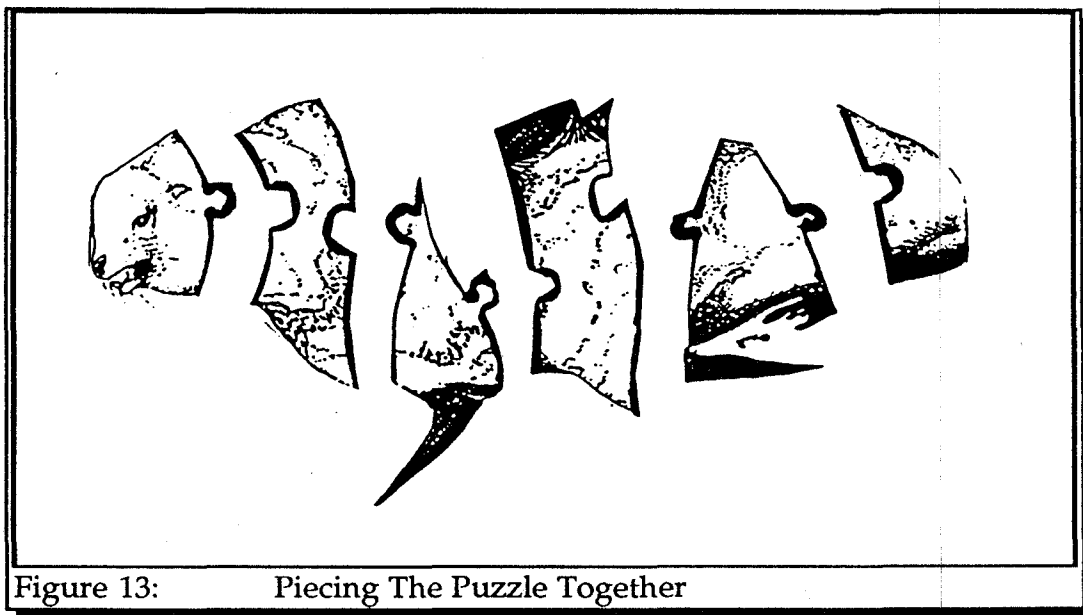


Figure 13: Piecing The Puzzle Together

The quality of tissues and other specimens collected either at or prior to death has more to do with an accurate diagnosis than history or clinical findings. Since in pinnipeds, history and clinical findings are often missing, tissue and specimen collection becomes even more crucial. Without proper handling, collection, preparation, preservation and shipping, valuable data, and scientific evidence admissible in a court of law, may be lost forever, and a legally defensible diagnosis never defined.

In addition, tissues shipped to accredited laboratories that follow quality assurance and quality control procedures and accomplish this through good laboratory practices, help insure that the diagnostic laboratory data generated will be of greatest use.

The main purposes in producing this *Pinniped Forensic Guide* are:

- to encourage standard operating procedures for field and necropsy room investigations of pinniped strandings and unusual mortality events;
- to assist in producing standard reference materials for comparative studies;
- to recommend analytical protocols that yield comparable diagnostic results; and,
- to improve the overall quality of tissue and specimen collection during pinniped beachings, strandings and unusual mortality events, so that a clinical diagnosis of the cause of an event may hold up in a court of law should such diagnosis be challenged.

Every specimen in every container in every styrofoam cooler in every shipment, must be considered as the most important specimen, and treated as if it alone could be the specimen that proves or disproves a case.

Anyone and everyone can perform the procedures in each Section of this Guide. The overall goal of this guide is to provide consistency in collection of information for use in establishing a disease or mortality event diagnosis. Information obtained from proper and dependable procedures yields the most effective clinical and laboratory diagnostic data, which in turn contributes to tentative and final diagnoses. The information obtained also furthers the known body of science on the particular species you are investigating, and provides reference materials for use in future studies and/or mortality events. Skillful techniques, with proper specimen and tissue collection and preservation, yield maximum reliability and credibility of scientific information.

Even if you have little or no experience with marine mammals, you can still offer significant value to the collection of scientific data, because the key to credible information is describing what you are seeing rather than what you think you should be seeing. Accurate observations and simple descriptive terms are the foundations upon which the veterinarians and researchers who are required to provide a final diagnosis as to cause of death base their decisions.

The more geographically isolated or remote you are from readily accessible clinical laboratory facilities, the more carefully you will need to observe and collect data to yield the most accurate and usable of diagnostic tissue/specimen samples and assertions. Never omit the simple diagnostic procedures and move directly to the more complex procedures, because this is ignoring the big picture, where subtle hints and changes may yield the most surprising details.

Always remain aware that the information you are collecting and recording is useful in multiple and meaningful ways. Not only can such data serve as an early warning system, cuing researchers and the public to potentially larger problems hidden in the background, but also as materials and data able to be fully admissible in a court of law to prove beyond a reasonable doubt that what the diagnostician interprets as the cause of an event can be argued before and interpreted by a judge or jury.

APPENDIX A**Formulations for Commonly Used Fixatives****10% Neutral Buffered Formalin:**

Formaldehyde solution (37-40%)	100 ml
Distilled water	900 ml
Sodium acid phosphate, monohydrate	4.0 grams
Disodium phosphate, anhydrous, pH=7.3	6.5 grams

AFA (Alcohol-Formalin-Acetic Mixture):

Formalin (as above)	4 ml
Ethanol (95%)	20 ml
Glacial acetic acid	0.5 ml
Distilled water	16 ml

APPENDIX B
Laboratories Accredited by the
American Association of Veterinary Laboratory Diagnosticians
July, 1992³²

1. County of Los Angeles, Department of Health Services Division, Comparative Medical and Veterinary Public Health Service, Downey, CA	16. The Division of Diagnostic Laboratories, School Veterinary Medicine, Tufts University, North Grafton, MA
2. Colorado Veterinary Diagnostic Laboratory, College of Veterinary Medicine, Colorado State University, Fort Collins, CO	17. Animal Health Diagnostic Laboratory, College of Veterinary Medicine, Michigan State University, East Lansing, MI
3. Department of Pathobiology, University of Connecticut, Storrs, CT	18. Minnesota Veterinary Diagnostic Laboratory, College of Veterinary Medicine, University of Minnesota, St. Paul, MN
4. Florida Veterinary Medicine Diagnostic Laboratory System, Florida Department of Agriculture, Kissimmee, FL	19. Mississippi Veterinary Diagnostic Laboratory, Mississippi Department of Agriculture, Jackson, MS
5. The Division of Comparative Pathology, University of Miami, Miami, FL	20. Veterinary Medical Diagnostic Laboratory, College of Veterinary Medicine, University of Missouri, Columbia, MO
6. Diagnostic Assistance Laboratory, College of Veterinary Medicine, University of Georgia, Athens, GA	21. State of Montana Animal Health Division, Diagnostic Laboratory, Bozeman, MT
7. Veterinary Diagnostic and Investigational Laboratory, College of Veterinary Medicine, University of Georgia, Tifton, GA	22. Nebraska Veterinary Diagnostic Laboratory System, Department of Veterinary Science, University of Nebraska, Lincoln, NE
8. Laboratories of Veterinary Diagnostic Medicine, College of Veterinary Medicine, University of Illinois, Urbana, IL	23. Veterinary Diagnostic Laboratory, New York State College of Veterinary Medicine, Cornell Univ, Ithaca, NY
9. Illinois Department of Agriculture, Animal Disease Laboratory, Galesburg, IL	24. North Carolina Veterinary Medical Diagnostic Laboratory System, North Carolina Department Agriculture, Raleigh, NC
10. Illinois Department of Agriculture, Animal Disease Laboratory, Centralia, IL	25. North Dakota State Veterinary Diagnostic Laboratory, Department of Veterinary Science, North Dakota State Univ, Fargo, ND
11. Indiana Animal Disease Diagnostic Laboratory and Southern Indiana Purdue Agricultural Center, Purdue University, West Lafayette, IN	26. Oklahoma Animal Disease Diagnostic Laboratory, College of Veterinary Medicine, Oklahoma State University, Stillwater, OK
12. Iowa Veterinary Diagnostic Laboratory, College of Veterinary Medicine, Iowa State University, Ames, IA	27. Animal Disease Research and Diagnostic Laboratory, South Dakota State University, Brookings, SD
13. Kansas Veterinary Diagnostic Laboratory, Department of Veterinary Diagnostics, College of Veterinary Medicine, Kansas State University, Manhattan, KS	28. & 29. Texas Veterinary Medical Diagnostic Laboratory, Texas A&M Univ System, Amarillo, TX & College Station, TX
14. Murray State University Veterinary Diagnostics and Research Center, Hopkinsville, KY	30. Washington Animal Disease Diagnostic Laboratory, College of Veterinary Medicine, Washington State University, Pullman, WA
15. Louisiana Veterinary Medical Diagnostic Laboratory, School of Veterinary Medicine, LSU, Baton Rouge, LA	31. Central Animal Health Laboratory, Wisconsin Department of Agriculture, Mineral Point Road, Madison, WI
	32. Wyoming State Veterinary Laboratory, Department of Veterinary Science, Laramie, WY

APPENDIX C

Sample Transfer Record

Project Name _____ Project No. _____

Date _____ Time _____ (24 hour clock)

day mo yr

Released By: _____ ID No. _____

name

At: _____

location

Date _____ Time _____ (24 hour clock)

day mo yr

Received By: _____ ID No. _____

name

At: _____

location

Comments:



Marine Forensics & Protected Resources Program

Chain of Custody Form



Sample description: _____

Case #/Seized Property #: _____

Origin of sample: _____

Name of sample collector/agent: _____

Address of sample collector/agent: _____

Phone Number: _____

Date collected/seized: _____

Collector's Signature: _____

Collector's Release signature: _____

Release date: _____ Method of transfer: _____

Every person subsequently in possession of the sample must complete a receipt/release box on the back of this form. (Each person must sign and date the form twice, once for receipt of the sample, and once for release).

Receipt signature: _____ Receipt date: _____
Print name/agency: _____
Release signature: _____ Release date: _____
Method of transfer to next person: _____

Receipt signature: _____ Receipt date: _____
Print name/agency: _____
Release signature: _____ Release date: _____
Method of transfer to next person: _____

Receipt signature: _____ Receipt date: _____
Print name/agency: _____
Release signature: _____ Release date: _____
Method of transfer to next person: _____

Receipt signature: _____ Receipt date: _____
Print name/agency: _____
Release signature: _____ Release date: _____
Method of transfer to next person: _____

Receipt signature: _____ Receipt date: _____
Print name/agency: _____
Release signature: _____ Release date: _____
Method of transfer to next person: _____

Receipt signature: _____ Receipt date: _____
Print name/agency: _____
Release signature: _____ Release date: _____
Method of transfer to next person: _____

Receipt signature: _____ Receipt date: _____
Print name/agency: _____
Release signature: _____ Release date: _____
Method of transfer to next person: _____

Receipt signature: _____ Receipt date: _____
Print name/agency: _____
Release signature: _____ Release date: _____
Method of transfer to next person: _____

Receipt signature: _____ Receipt date: _____
Print name/agency: _____
Release signature: _____ Release date: _____
Method of transfer to next person: _____

REFERENCES

1. Roletto, J. and Mazzeo, J., 1990. Identification of North American Marine Mammals, in Handbook of Marine Mammal Medicine: Health, Disease and Rehabilitation, L.A. Dierauf (ed.), CRC Press, Boca Raton, FL, pp. 399-468.
2. Geraci, J.R. and Lounsbury, V.J., 1993. Pinnipeds, in Marine Mammals Ashore: A Field Guide for Strandings, A Texas A & M Sea Grant Publication, Galveston, TX, pp. 58-69.
3. Wilkinson, D. M., 1991. Report To: Assistant Administrator for Fisheries, Program Review of the Marine Mammal Stranding Networks, National Oceanic and Atmospheric Administration, Appendix B.
4. Geraci, J.R. and Lounsbury, V.J., 1993. Specimen and Data Collection, in Marine Mammals Ashore: A Field Guide for Strandings, A Texas A & M Sea Grant Publication, Galveston, TX, p. 179.
5. Dierauf, L.R., 1990. Pinniped Blood Collection, in Handbook of Marine Mammal Medicine: Health, Disease and Rehabilitation, L.A. Dierauf (ed.), CRC Press, Boca Raton, FL, pp. 582-584.
6. Geraci, J.R. and Lounsbury, V.J., 1993. Specimen and Data Collection, in Marine Mammals Ashore: A Field Guide for Strandings, A Texas A & M Sea Grant Publication, Galveston, TX, p. 179.
7. Williams, T.D., Williams, A.L. and Stoskopf, M., 1990. Marine Mammal Anesthesia (Pinnipeds), in Handbook of Marine Mammal Medicine: Health, Disease and Rehabilitation, L.R. Dierauf (ed.), CRC Press, Boca Raton, FL, pp. 183-188.
8. Bossart, G.D. and Dierauf, L.R., 1990. Marine Mammal Clinical Laboratory Medicine, in Handbook of Marine Mammal Medicine: Health, Disease and Rehabilitation, L.R. Dierauf (ed.), CRC Press, Boca Raton, FL, p. 47.

9. Spraker, T.R, 1985. Basic Necropsy Procedures, in *Clinical Textbook for Veterinary Technicians*, D.M. McCurnin (ed.), W. B. Saunders, Philadelphia, pp. 483-484.
10. Sweeney, J. C., 1990. Surgery, in *Handbook of Marine Mammal Medicine: Health, Disease and Rehabilitation*, L.R. Dierauf (ed.), CRC Press, Boca Raton, FL, pp. 222-224.
11. Cowell, R.L. and Tyler, R.D., 1989. Cytology of Cutaneous Lesions, in *The Veterinary Clinics of North America: Small Practice*, vol. 19, no. 4, July, B.W. Perry (ed.), W.B. Saunders Co., Philadelphia, PA, pp. 769-775.
12. National Marine Fisheries Service, Southeast Fisheries Center, Charleston Laboratory, 1993. *Forensic Manual (for the Analysis of Marine Animal Tissues)*, [Draft], p. 42.
13. Dierauf, L.R., 1990. Aging the Pinniped via Dentition, in *Handbook of Marine Mammal Medicine: Health, Disease and Rehabilitation*, CRC Press, Boca Raton, FL, p. 559.
14. Buck, C.D. and Schroeder, J.P., 1990. Public Health Significance of Marine Mammal Disease, in *Handbook of Marine Mammal Medicine: Health, Disease and Rehabilitation*, CRC Press, Boca Raton, FL, pp. 163-174.
15. Strafuss, Albert, C., 1988. Descriptive Writing of Pathologic Changes, in *Necropsy: Procedures and Basic Diagnostic Methods for Practicing Veterinarians*, A. Strafuss (ed.), Charles C. Thomas, Publisher, Springfield, IL, pp. 43-49.
16. Strafuss, Albert, C., 1988. Removal of the Brain and Spinal Cord, in *Necropsy: Procedures and Basic Diagnostic Methods for Practicing Veterinarians*, A. Strafuss (ed.), Charles C. Thomas, Publisher, Springfield, IL, pp. 30-32.
17. Dierauf, L.R., 1990. Marine Mammal Parasitology, in *Handbook of Marine Mammal Medicine: Health) Disease and Rehabilitation*, CRC Press, Boca Raton, FL, pp. 89-90.

18. Brown, H. W. and Neva, F.A., 1983. Technical Diagnostic Methods, Basic Clinical Parasitology, Appleton-Century-Crofts, Norwalk, CT, p. 315.
19. Dunn, J. L., 1990. Microbial Sampling Techniques, in Handbook of Marine Mammal Medicine: Health, Disease and Rehabilitation, L.R. Dierauf (ed.), CRC Press, Boca Raton, FL, pp. 73-74.
20. Kennedy-Stoskopf, S., 1990. Immunology of Marine Mammals, in Handbook of Marine Mammal Medicine: Health, Disease and Rehabilitation, L.R. Dierauf, (ed.), CRC Press, Boca Raton, FL, pp. 115-124.
21. Kennedy-Stoskopf, S., 1990. Virus Isolation--An Overview, In Handbook of Marine Mammal Medicine: Health, Disease and Rehabilitation, L.R. Dierauf (ed.), CRC Press, Boca Raton, FL, pp. 97.
22. National Marine Fisheries Service, Southeast Fisheries Center, Charleston Laboratory, 1993. Forensic Manual (for the Analysis of Marine Animal Tissues), [Draft], p. 60.
23. Leland, D. S., 1992. Collection and Transport of Specimens, Laboratory Diagnosis of Viral Infections, 2nd Edition, E. H. Lennette (ed.), Marcel Dekker, Inc., New York, pp. 3-43.
24. Amdur, M.O., Doull, J., and Klassen, C.D., 1991. Casarett and Doull's Toxicology, 4th Edition, Pergamon Press, New York, pp. 47-48.
25. Osweiler, G.D., Carson, T.C., Buck, W.B. and Van Gelder, G.A., 1985. Clinical and Diagnostic Veterinary Toxicology, Kendall/Hunt Publishing Co, Dubuque, IA, pp. 451-453.
26. Amdur, M.O., Doull, J., and Klassen, C.D., 1991, Casarett and Doull's Toxicology, 4th Edition, Pergamon Press, New York, pp. 47-48.

27. National Marine Fisheries Service, Southeast Fisheries Center, Charleston Laboratory, 1993. Forensic Manual (for the Analysis of Marine Animal Tissues), [Draft], pp. 98-106.
28. Stegeman, J. J., Hahn, M. E. and Moore, M. J., (undated) Tissue Request and Sampling Protocol for Freshly Dead Marine Mammals, Woods Hole Oceanographic Institution, Woods Hole, MA, 1 page.
29. National Marine Fisheries Service, Southeast Fisheries Center, Charleston Laboratory, 1993. Forensic Manual (for the Analysis of Marine Animal Tissues), [Draft], p. 14.
30. National Marine Fisheries Service, Southeast Fisheries Center, Charleston Laboratory, 1993. Forensic Manual (for the Analysis of Marine Animal Tissues), [Draft], PP. 74-75.
31. Geraci, J. R. and Lounsbury, V. J., 1993. Specimen and Data Collection, Marine Mammals Ashore: A Field Guide for Strandings, A Texas A & M Sea Grant Publication, Galveston, TX, p. 204.
32. Strafuss, R.C., 1992. Necropsy, in Laboratory Procedures for Veterinary Technicians, P.W. Pratt, (ed.), American Veterinary Publications, Inc., Goleta, CA, pp. 471-474.
33. U.S. Department of Agriculture, Animal and Plant Health Inspection Service, Veterinary Services, 1992. Directory of Animal Disease Diagnostic Laboratories, in cooperation with the American Association of Veterinary Laboratory Diagnosticians (AAVLD), July.